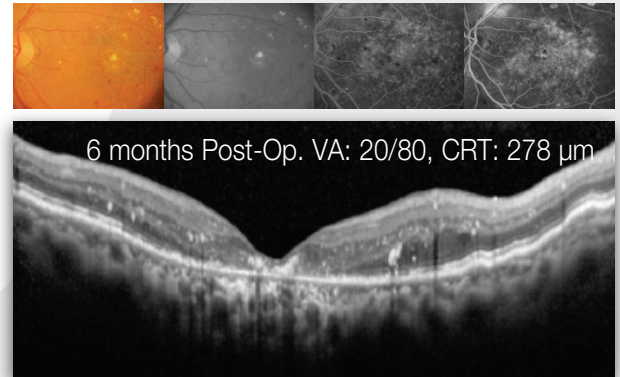
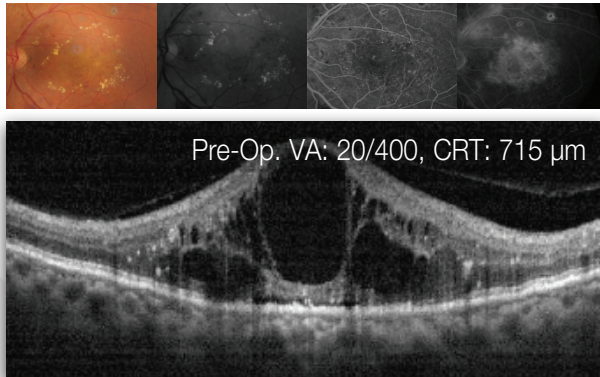




MicroPulse™ Case Report

First, do no harm

DME Refractive to 6 Injections of Bevacizumab | IQ 577™



Physician: José A. Cardillo, MD | São Paulo, Brazil

Patient: Difficult case of diffuse diabetic macular edema who received 6 monthly injections of bevacizumab with no results.

Sandwich Technique Treatment Parameters

Laser | Wavelength: IQ 577 | 577 nm

Step 1: Barely Visible Low Energy/Short Pulse Duration

Mode: Continuous-wave

Spot Size on SLA: 100 μm

Contact Lens: Area Centralis

Power: Adjusted to show a barely visible lesion

Duration: 10 ms

Duty Cycle: 100%

Evidence of Laser Treatment on FA: Yes

Technique: Deliver barely visible lesions 1 burn apart in a grid pattern 360° around the fovea, up to 500 μm from the center of the FAZ

Step 2: Subvisible MicroPulse Laser Therapy (MPLT)

Mode: MicroPulse

Spot Size on SLA: 100 μm

Contact Lens: Area Centralis

Power: 20% increase from power used in CW mode (Step 1)

Duration: 200 ms

Duty Cycle: 10% or less

Evidence of Laser Treatment on FA: No

Technique: Paint contiguously all areas of leakage within 500 μm from the FAZ's center.

Treatment techniques and opinions presented in this case report are those of the author. IRIDEX assumes no responsibility for patient treatment or outcome.



IRIDEX

Elegantly simple solutions™