

MicroPulse® Results Exceed Expectations in a Treatment-Naïve Patient with Center-Involving Diabetic Macular Edema



Munir Escaf, MD, is a vitreoretinal surgeon at Centro Oftalmológico Carriazo in Barranquilla, Atlántico, Colombia.

During the 2014 American Academy of Ophthalmology meeting, I took the opportunity to attend several lectures on the topic of MicroPulse Laser Therapy, a modality designed to treat retinal and glaucoma disorders while avoiding laser-induced thermal tissue damage. I also spoke personally with world-renowned expert Dr. Sam Mansour. Though I was interested in trying MicroPulse, I was uneasy about the safety of using a laser therapy through the fovea, so I asked about his experience and insights in this area. After our discussion about the capabilities and benefits of MicroPulse for macular focal treatment compared with conventional thermal laser, I felt confident enough to use it in my practice.

PATIENT HISTORY

Earlier this year, I began treating patients with MicroPulse, including a 62-year-old Latin male who was referred to me for evaluation because he had been experiencing decreased vision in his right eye for more than a month. He had been diagnosed 25 years prior with type 2 diabetes. His diabetes was poorly controlled, he was hypertensive and he had no prior retinal treatment. On clinical exam the optic nerve appeared normal, but a large number of microaneurysms were visible throughout the macula and in other quadrants. Hard exudates, most more than 500 µm from the fovea, were also present. The patient's visual acuity (VA) was 20/800 and optical coherence tomography (OCT) measured central retinal thickness (CRT) at 355 µm.

I recommended that we treat him with MicroPulse on that day. Because my philosophy is to treat each patient as an individual, I don't automatically use an intravitreal anti-VEGF agent or steroid as a first-line therapy for diabetic macular edema (DME), unless the

edema is very severe. I prefer first to see what outcome the less-invasive laser alone can produce. Also, in our Colombian healthcare system, it is easier to gain approval to provide laser treatment than any type of intravitreal treatment; therefore, laser is usually the fastest way to begin helping patients.

TXCELL-GUIDED MICROPULSE LASER THERAPY AS FIRST-LINE TREATMENT

The patient agreed to have MicroPulse Laser Therapy immediately. I began the treatment session with the IRIDEX IQ 577™ laser in continuous-wave mode at 70 mW of power. I gradually increased the power while delivering spots outside the macula until I saw the slightest tissue response, which occurred at 90 mW. At that point, I switched the laser to MicroPulse mode and, multiplying the test burn power by four to 360 mW, applied 882 confluent spots to the posterior pole, including the fovea.

RESULTS AS FIRST-LINE TREATMENT

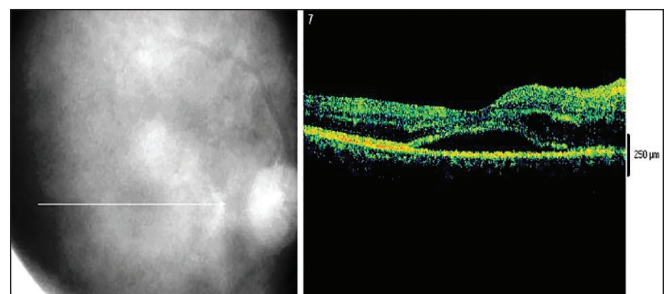


Figure 1A. Feb. 19, 2015 | Pre MicroPulse | CRT 355 µm | VA 20/800

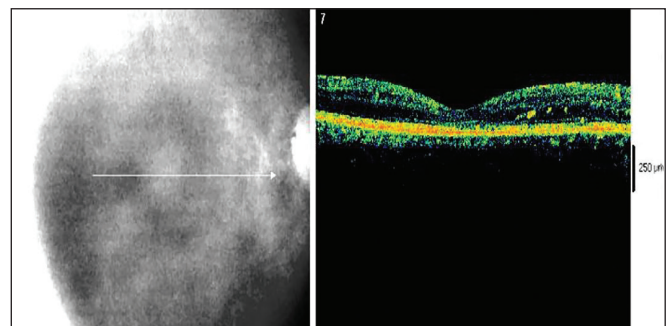


Figure 1B. March 31, 2015 | 5 weeks post MicroPulse | CRT 166 µm | VA 20/50

“Overall, as a newcomer to [MicroPulse Laser Therapy], I have been overwhelmed by the ability it gives me to treat macular edema effectively, directly at the affected area, without collateral tissue damage... My confidence in the safety of this treatment was firmly established after just a few cases.”

I used a 200- μ m spot size, a 200-ms exposure duration and a 5% duty cycle. I also used the TxCell™ Scanning Laser Delivery System to apply the spots efficiently in a 7x7 grid pattern. (Table 1)

The patient returned for follow-up 5 weeks later as scheduled. Clinical exam revealed that some microaneurysms and exudates remained; however, the macular edema was completely resolved. CRT decreased from its pre-laser level of 355 μ m to 166 μ m. VA improved from 20/800 to 20/50 (Figure 1A, 1B). The patient reported that he was very pleased with the improvement in his vision.

Based on my research into MicroPulse, I wasn't surprised it had an effect in this patient; yet the complete drying of the macula far exceeded my expectations. I examined the patient again at 9 weeks and 15 weeks after MicroPulse treatment, and his CRT and VA were maintained. He was scheduled to return for his next visit 4 months later. If at that time the macular edema has recurred, I will perform fluorescein angiography to identify areas of leakage and retreat with MicroPulse Laser Therapy. Because recurrence of DME could indicate retinal ischemia, which upregulates VEGF, I would also recommend an anti-VEGF injection.

MICROPULSE HAS BROAD APPLICATIONS

Since I first used MicroPulse in February 2015, I have also used it to treat edema secondary to branch and central retinal vein occlusion, and most of the cases of central serous retinopathy I have treated have completely resolved in 3 to 4 weeks. Overall, as a newcomer to the modality, I have been overwhelmed by the ability it gives me to treat macular edema effectively, directly at the affected area, without collateral tissue damage.

I would advise retinal physicians who are considering adopting MicroPulse to lose the fear of treating the fovea. My confidence in the safety of this treatment was firmly established after just a few cases. I would also recommend use of the TxCell delivery device, as it has decreased my treatment time by 90%. In addition, I would note that because the IQ 577 can be used to perform both conventional photocoagulation and MicroPulse treatments, it is a good value for a practice. Finally, MicroPulse has expanded the ways in which I can use laser as an effective treatment tool, thus increasing my capacity to tailor a treatment regimen to the individual needs of each of my patients.

Table 1. TREATMENT PARAMETERS

IRIDEX IQ 577™ laser with MicroPulse and the TxCell Scanning Laser Delivery System for center-involving DME

- Wavelength: 577 nm
- Spot size on slit lamp adapter: 200 μ m
- Contact lens: Mainster Focal/Grid (Ocular Instruments)
- Power: 360 mW
- Exposure duration: 200 ms
- Duty cycle: 5%
- MicroPulse Delivery: 882 confluent spots in a 7x7 TxCell grid pattern applied to the posterior pole, including the fovea



To learn more about MicroPulse, go to www.iredex.com/micropulse

Treatment techniques and opinions presented in this case report are those of the author. IRIDEX lasers are cleared for retinal photocoagulation of vascular and structural abnormalities of the retina and choroid; and iridotomy, iridectomy and trabeculoplasty in angle-closure glaucoma and open-angle glaucoma. IRIDEX assumes no responsibility for patient treatment and outcome. IRIDEX, IRIDEX logo, and MicroPulse are registered trademarks, and IQ 577 and TxCell are trademarks of IRIDEX Corporation.

IRIDEX | 1212 Terra Bella Avenue | Mountain View, CA 94043 | 800.388.4747 (U.S. inquiries) | info@iredex.com (U.S. & int'l inquiries) | www.iredex.com

© 2015 IRIDEX Corporation. All rights reserved. LT0626