

# MicroPulse® Laser Therapy as an Adjunct to Intravitreal Triamcinolone for Chronic Recurrent Idiopathic Cystoid Macular Edema



**Margaret Wong, MD**, practices at Eye Consultants of Atlanta in Georgia. She specializes in diseases and surgery of the retina, vitreous and macula and ocular inflammatory disease.



**Robert L. Halpern, MD**, is a retina surgeon who specializes in serious ocular conditions at Eye Consultants of Atlanta in Georgia, where he is also Director of the fellowship program. Dr. Halpern also serves as Chairman, Section of Ophthalmology, for Piedmont Hospital.

MicroPulse Laser Therapy can be an effective treatment for macular edema due to a variety of causes. Studies have shown that it produces results comparable to those obtained with the use of conventional thermal laser without laser-induced damage to retinal tissue.<sup>1-4</sup> With this level of safety, MicroPulse can be used to treat fovea-involving edema, providing vitreoretinal specialists with a valuable additional therapeutic option. Since we consider laser to be a more definitive treatment that produces more durable results than other options, and because MicroPulse significantly expands the range of cases to which we can apply it, we recently obtained an IRIDEX IQ 577™ laser for our practice.

The IQ 577, a yellow wavelength laser, can be used for multiple indications with either continuous-wave or optional MicroPulse modes. In MicroPulse mode, the IQ 577 can be used to treat diabetic macular edema (DME), central serous retinopathy, macular edema associated with branch retinal vein occlusion and central retinal vein occlusion and cystoid macular edema (CME) secondary to uveitis. We recently used MicroPulse supplemented with one intravitreal injection of triamcinolone acetonide (Triesence, Alcon) to successfully treat a patient who had chronic, recurrent idiopathic CME.

---

***“With this level of safety, MicroPulse can be used to treat fovea-involving edema, providing vitreoretinal specialists with a valuable additional therapeutic option.”***

---

## PATIENT HISTORY AND PRESENTATION

A 43-year-old white female had been previously diagnosed with bilateral idiopathic CME. All testing, including erythrocyte sedimentation rate, antinuclear antibody, rapid plasma reagin, angiotensin-converting enzyme, complete blood count and chest X-ray, which had been ordered to identify a potential cause were

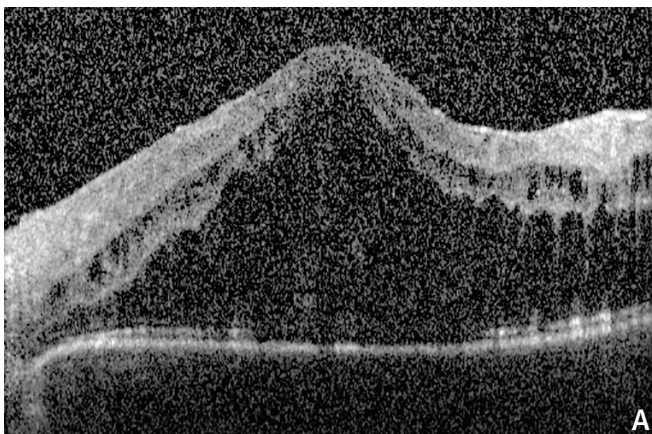
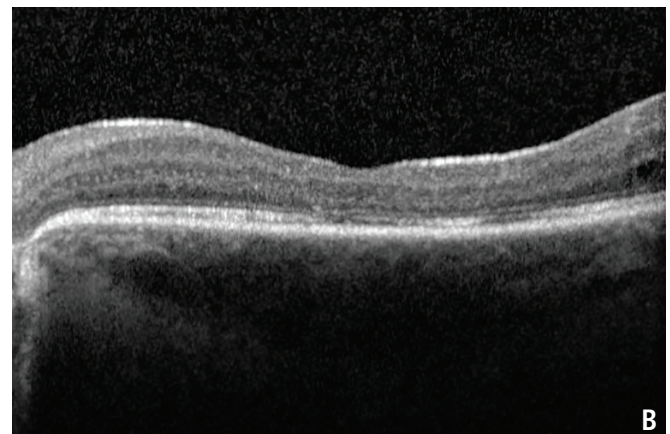


Figure 1. (A) Sept. 2, 2014 | Pre MicroPulse | CRT 938 μm | VA counting fingers at 1 foot



(B) Jan. 8, 2015 | 18 weeks post MicroPulse, 14 weeks post steroid injection | CRT 197 μm | VA 20/400

*“...we have no doubt that [MicroPulse] is capable of reducing macular edema in even difficult cases... It’s reassuring to know that we can treat the fovea safely...”*

negative. In 2010, she had been treated with ketorolac drops twice a day in both eyes for 2 months, which was not effective for the left eye. For the next few years, CME recurred in the left eye approximately every 6 months to a year, and each time the patient received a Triescence injection.

On Sept. 2, 2014, upon clinical examination, the retina OS appeared to be severely edematous and cystic changes were observed. Central retinal thickness (CRT) as measured by spectral-domain OCT was 938 µm and visual acuity (VA) was counting fingers at 1 foot. **(Figure 1A)** Rather than administering another steroid injection, which carries the risk of increased intraocular pressure (IOP) and the development of cataract, we discussed with the patient the option of MicroPulse and she consented to the laser treatment.

### MICROPULSE LASER THERAPY AND SUPPLEMENTAL TRIAMCINOLONE INJECTION

The IRIDEX IQ 577 laser was used in MicroPulse mode to deliver the treatment with the following parameters: spot size 200 µm, power 400 mW, exposure duration 200 ms and duty cycle 5%. **(Table 1)** An Ocular

**Table 1. TREATMENT PARAMETERS**

- IRIDEX IQ 577 Laser with MicroPulse for Idiopathic CME
- Wavelength: 577 nm
- Spot size on slit lamp adapter: 200 µm
- Contact lens: Ocular Instruments fundus laser lens
- Power: 400 mW
- Exposure duration: 200 ms
- Duty cycle: 5%
- MicroPulse Delivery: 235 spots applied to all areas of edema, including the fovea, as observed on clinical exam.

Instruments fundus laser lens was used for visualization. A total of 235 spots were applied to the entire edematous area including the fovea. Typically, MicroPulse takes approximately 3 months to show a response.

When the patient returned 1 month later on Oct. 2, 2014, her CRT measured 1,057 µm and VA was counting fingers at 2 feet. Due to the continued increase in CRT, I thought the immediate effect of Triescence would be beneficial to reduce the CRT, while waiting for the slower, yet more durable outcomes of MicroPulse to take effect.

Five days later, on Oct. 7, 2014, VA remained counting fingers at 2 feet, but CRT improved to 440 µm. Six weeks later, CRT improved further to 196 µm and VA also improved to counting fingers at 3 feet. By Jan. 8, 2015, no edema was present. CRT measured 197 µm and VA improved to 20/400. **(Figure 1B)** In this case, MicroPulse as an adjunct to Triescence demonstrated a more effective response than I previously observed with Triescence alone. And, with the durability of MicroPulse I anticipate eliminating the need for further injections.

### EFFICACY WITH A REASSURING LEVEL OF SAFETY

Now that we have been using MicroPulse in our practice for approximately 7 months, we have no doubt that it’s capable of reducing macular edema in even difficult cases. We have also fully realized that it’s an efficient, easy-to-perform procedure that is very forgiving in terms of treatment location. It’s reassuring to know that we can treat the fovea safely, and if a patient can’t maintain gaze in front or moves during the treatment, no damage to other retinal tissue occurs. ■

### REFERENCES

1. Lavinsky D, Cardillo JA, Melo LA Jr., et al. Randomized clinical trial evaluating mETDRS versus normal or high-density micropulse photocoagulation for diabetic macular edema. *Invest Ophthalmol Vis Sci.* 2011;52(7):4314-4323.
2. Gupta B, Elagouz M, McHugh D, et al. Micropulse diode laser photocoagulation for central serous chorioretinopathy. *Clin Experiment Ophthalmol* 2009;37(8):801-805.
3. Inagaki K, Ohkoshi K, Ohde S, et al. Subthreshold micropulse photocoagulation for persistent macular edema secondary to branch retinal vein occlusion including best-corrected visual acuity greater than 20/40. *J Ophthalmol.* 2014;2014:251257.
4. Vujosevic S, Bottega E, Casciano M, Pilotto E, Convento E, Midena E: Microperimetry and Fundus Autofluorescence in Diabetic Macular Edema: Subthreshold Micropulse Diode Laser Versus Modified Early Treatment Diabetic Retinopathy Study Laser Photocoagulation. *Retina* 2010;30(6):908-916.



To learn more about MicroPulse, go to [www.irdex.com/micropulse](http://www.irdex.com/micropulse)

Treatment techniques and opinions presented in this case report are those of the author. IRIDEX lasers are cleared for retinal photocoagulation of vascular and structural abnormalities of the retina and choroid; and iridotomy, iridectomy and trabeculoplasty in angle-closure glaucoma and open-angle glaucoma. IRIDEX assumes no responsibility for patient treatment and outcome. IRIDEX, IRIDEX logo, and MicroPulse are registered trademarks, and IQ 577 is a trademark of IRIDEX Corporation.

IRIDEX | 1212 Terra Bella Avenue | Mountain View, CA 94043 | 800.388.4747 (U.S. inquiries) | info@irdex.com (U.S. & int'l inquiries) | www.irdex.com

© 2015 IRIDEX Corporation. All rights reserved. LT0622