

MicroPulse™ Laser Therapy as an Effective, First-Line Treatment for Juxtafoveal Telangiectasia



Sam E. Mansour, MSc, MD, FRCS(C), FACS, is medical director of Virginia Retina Center in Warrenton, Va., and clinical professor of ophthalmology at The George Washington University in Washington, D.C. He has extensive experience and expertise in the management of patients with vitreoretinal disorders. Over the past 20 years, Dr. Mansour has been involved in multiple areas of basic science and clinical retinal research.

Historically, no treatment for the group of retinal disorders categorized as juxtafoveal telangiectasia (JXT) has been ideal. The most commonly used treatment has been conventional laser photocoagulation, which poses the risk of scarring that can expand into the center of the fovea over time. Anti-VEGF agents and steroids have questionable efficacy at best in JXT, and it's typically resistant to topical steroids and non-steroidals as well. Optimal therapy for JXT would enable treatment of the vessel wall sufficient to stop the macular edema-causing leakage without inducing pigmentary changes or damaging the deeper retinal layers. An option that fits those criteria is MicroPulse Laser Therapy (MPLT). In my practice, MPLT is the first-line treatment for JXT.

The case from my patient files described here illustrates the effectiveness of MPLT in eliminating JXT-associated macular edema, especially in comparison to conventional laser photocoagulation.

PATIENT HISTORY AND PRESENTATION

The patient is a 72-year-old male whose only treatment for JXT (OD) prior to MPLT was with a continuous-wave (CW) laser set to subthreshold settings. He had previously been diagnosed with amblyopia in his right eye. During the 4 months following the CW laser treatment, his central macular thickness (CMT), as measured by OCT, continued to increase. This wasn't surprising because the retinal lesions in JXT are very close to, and often within, the center of the fovea. CW laser, even on the lowest subthreshold settings, cannot be applied to the fovea without causing permanent outer retinal damage. The result is typically a donut-shaped treatment pattern that doesn't adequately target the abnormal blood vessels responsible for the edema.

TXCELL-GUIDED MICROPULSE DELIVERY

Given the eye's lack of response to conventional laser treatment, the patient agreed to undergo MPLT. Prior to his MPLT session, his best-corrected visual acuity (BCVA) was 20/100-1, and CMT was 317 μm (Figure 1). I performed the treatment with the IRIDEX IQ 577™ (yellow) laser, incorporating the TxCell™ Scanning Laser Delivery System and a Mainster (standard) focal/grid contact lens. Delivering six 7x7

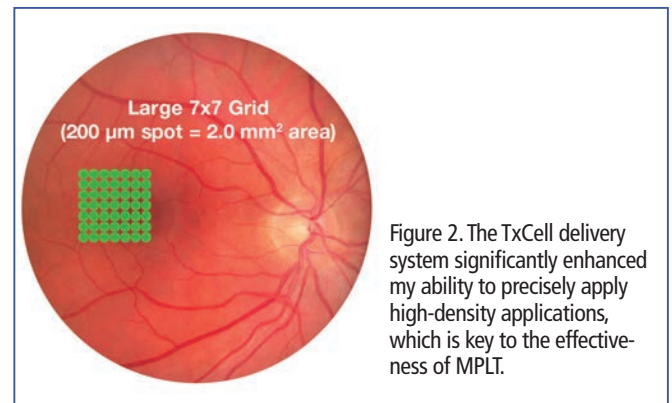


Figure 2. The TxCell delivery system significantly enhanced my ability to precisely apply high-density applications, which is key to the effectiveness of MPLT.

high-density grid patterns, I used 800 mW with a 5% duty cycle and used a 200- μm spot size and 200-ms duration. I no longer perform CW test burns in order to choose the power for my MPLT treatments. I'm able to select the power based on experience and patient presentation.

In this case, as in all of my MPLT cases, the TxCell delivery system significantly enhanced my ability to precisely apply high-density applications, which is key to the effectiveness of MPLT (Figure 2).^{1,2} I can choose grid, circular or triple arc patterns, all of which are adjustable. The selected pattern grid is projected onto the treatment area and shows me where the laser energy will be placed.

By seven weeks after MPLT, the patient's CMT had decreased from 317 μm to 280 μm . It continued to decrease further until his final visit 6 months later. At that visit, CMT was 251 μm (Figure 3). His visual acuity was 20/100, limited by both his amblyopia and the pigmentary changes from his previous CW laser therapy. He has not required any additional treatment for JXT-related macular edema.

BENEFITS FOR THE PATIENT AND THE PRACTICE

As this case demonstrates, MPLT is very effective in the treatment of JXT and has a unique advantage over all other options: direct treatment of the abnormal blood vessels whether they are near to, or in the center of, the fovea. It's been a savior for my JXT patients, who often have been subjected to a barrage of other treatments by the time they arrive at our clinic.

I use MPLT, either alone or in combination with other options, to treat many other conditions, including macular edema related to diabetes, retinal vein occlusion and pseudophakia. It's also very effective in the management of central serous retinopathy. In these cases, too, MPLT usually greatly reduces patients' treatment burden and costs to the healthcare system. The results are not always immediate and instead sometimes occur gradually over time. While this may be worrisome to physicians using MPLT for the first time, it does not take long for those concerns to subside.

"[MicroPulse] has been a savior for my JXT patients, who often have been subjected to a barrage of other treatments by the time they arrive at our clinic."

MPLT benefits not only my patients, but also my practice. Because it is efficient, it's easy to work into the daily patient flow. The treatment is made even more efficient with the addition of the TxCell Scanning Laser Delivery System, which also makes the treatments easier and less tiring for me. I can also use the same IRIDEX IQ 577 laser that I use for MPLT in CW mode when a situation calls for it, which saves on space and expenditures. ■



To learn more about MicroPulse, go to www.irdex.com/micropulse

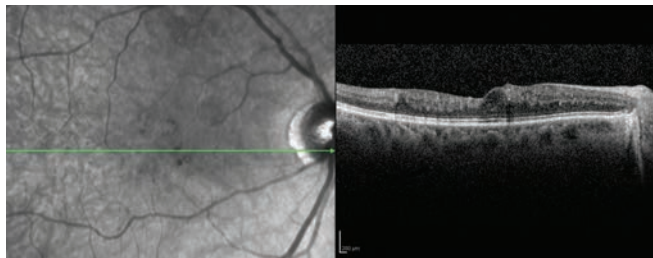


Figure 1. September 2012 | right eye | 8 months prior to MPLT
CMT 317 μm | VA 20/100-1.

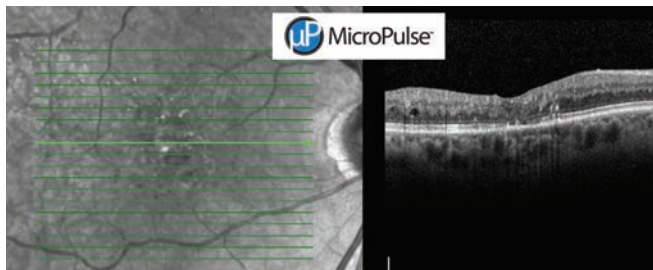


Figure 3. November 2013 | right eye | 6 months post MPLT
CMT 251 μm | VA 20/100 (limited by amblyopia).

TREATMENT PARAMETERS

IQ 577 MPLT with TxCell for Juxtafoveal Telangiectasia

- Wavelength: 577 nm
- Spot size on slit lamp adapter: 200 μm
- Contact lens: Mainster (standard) focal/grid
- Power: 800 mW
- Exposure duration: 200 ms
- Duty cycle: 5%
- TxCell-Guided MicroPulse Delivery: Six patterns of 7x7 high-density grid to blanket cover edematous area.

REFERENCES

1. Lavinsky D, Cardillo JA, Melo LA Jr, et al. Randomized clinical trial evaluating mETDRS versus normal or high-density micropulse photocoagulation for diabetic macular edema. *Invest Ophthalmol Vis Sci.* 2011;52(7):4314-23.
2. Luttrull JK, Sramek C, Palanker D, et al. Long-term safety, high-resolution imaging, and tissue temperature modeling of subvisible diode micropulse photocoagulation for retinovascular macular edema. *Retina.* 2012;32(2):375-386.

Treatment techniques and opinions presented in this case report are those of the author. IRIDEX assumes no responsibility for patient treatment and outcome. IRIDEX, IRIDEX logo are registered trademarks, MicroPulse, TxCell, and IQ 577 are trademarks of IRIDEX Corporation.

IRIDEX | 1212 Terra Bella Avenue | Mountain View, CA 94043 | 800.388.4747 (U.S. inquiries) | info@irdex.com (U.S. & int'l inquiries) | www.irdex.com

© 2014 IRIDEX Corporation. All rights reserved. LT0593

IRIDEX lasers are cleared for retinal photocoagulation of vascular and structural abnormalities of the retina and choroid; and iridotomy, iridectomy and trabeculoplasty in angle-closure glaucoma and open-angle glaucoma.