

TxCell-Guided MicroPulse™ Laser Therapy Increases Treatment Efficiency for Diabetic Macular Edema



Johnny Tang, MD, is an associate professor in the department of ophthalmology at the University of Kansas and the director of medical retina and vitreoretinal surgery at the University of Kansas Medical Center in Kansas City, Kan.

The IRIDEX IQ 577™ Laser System has been a wonderful addition to my practice, allowing me to treat a full range of retinal disorders efficiently with just one device. The 577 nm wavelength has high transmission through dense ocular media, and its low light scattering results in less power needed for the intended retinal irradiance which increases comfort for patients. The system's dual port simplifies setup of delivery devices, and the touchscreen interface is user friendly.

IQ 577 VERSATILITY FOR CONVENTIONAL & MICROPULSE TREATMENTS

In conventional mode, the IQ 577 can be used for any retinal application for which I would choose the yellow wavelength, including retinopexies, iridotomies, panretinal photocoagulation and suture lysis. In addition, I have used the fovea-friendly MicroPulse mode to treat several retinal conditions, including diabetic macular edema (DME), refractory cystoid macular edema (CME) in uveitis and CME associated with retinal vein occlusion. In addition, my glaucoma-specialist colleagues use the IQ 577 to perform MicroPulse laser trabeculoplasty.

In the following case report, I describe how one MicroPulse session completely resolved DME in one of my patients, without the use of any other, more invasive, therapies.

PATIENT HISTORY AND PRESENTATION

The patient is a 79-year-old female with insulin-dependent diabetes mellitus and a history of nonproliferative diabetic retinopathy (NPDR) OU. She first came to see me in February of 2014, one year after receiving

the last in a series of anti-VEGF injections for DME in her left eye. Her chief complaint was worsening foggy vision in that eye. Her best-corrected visual acuity (BCVA) that day was 20/25 OD, which was her usual baseline, and 20/60 OS, which represented a two-line decrease from her usual baseline.

“[TxCell-Guided MicroPulse] made the process much more efficient and ensured that the treatment was evenly distributed over the tissue.”

Examination revealed NPDR OU and clinically significant DME OS. Central subfield thickness (CST) OS was 340 μm according to OCT (Spectralis SD-OCT, Heidelberg) (Figure 1). The patient and I discussed treatment possibilities and she was hesitant to undergo additional anti-VEGF injections or use a topical NSAID daily. She opted instead for MicroPulse laser therapy.

TXCELL-GUIDED MICROPULSE DELIVERY

Prior to the patient's MicroPulse laser therapy, I performed a test spot away from the macula. I put the laser in continuous-wave mode, and using a 200-μm spot size and a 150 ms duration, I titrated the power

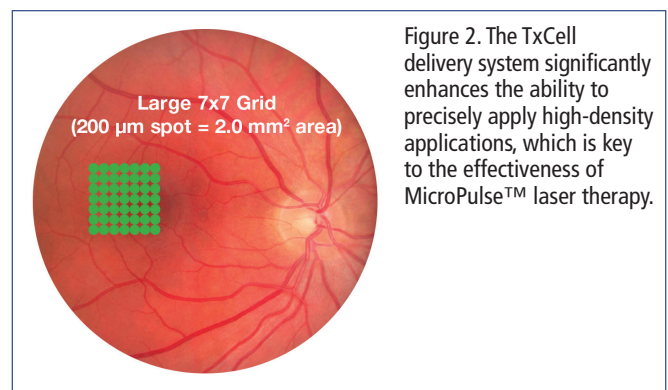


Figure 2. The TxCell delivery system significantly enhances the ability to precisely apply high-density applications, which is key to the effectiveness of MicroPulse™ laser therapy.

upward until I observed a barely visible tissue reaction, which for this particular patient occurred at 150 mW. To treat, I switched the laser to MicroPulse mode and set the following parameters: 300 mW power, 200- μ m spot size, 200-ms duration and 5% duty cycle. I delivered 204 confluent spots in a 3x3 grid pattern over the areas of edema (Table 1).

Placing such a high number of spots manually would be difficult in such a confined treatment area. However, I used the IRIDEX TxCell™ Scanning Laser Delivery System to guide my placement of each spot in a grid pattern (Figure 2). This made the process much more efficient and ensured that the treatment was evenly distributed over the tissue.

FAST & EFFECTIVE OUTCOME

The patient returned for her follow-up visit 1 month after MicroPulse laser therapy, stating that her vision in the treated eye was much better. BCVA in that eye had returned to her usual baseline of 20/40, the macular edema had completely resolved, and CST measured 280 μ m (Figure 3). The patient was pleased to have such a good result after just one treatment. We scheduled her next follow-up visit for 3 months later.

“[MicroPulse] does not damage retinal tissue and can be repeated safely.”

If necessary, I would not hesitate to treat this patient again with MicroPulse laser therapy. MicroPulse finely controls the thermal effects of photocoagulation, so it does not damage retinal tissue and can be repeated safely. In fact, because there is no visible effect on the tissue either during or after treatment, new users of the technology sometimes tend to undertreat. Typically, it does not take long for confidence in the safety and efficacy of MicroPulse laser therapy to reverse this tendency. ■



To learn more about MicroPulse, go to www.iredex.com/micropulse

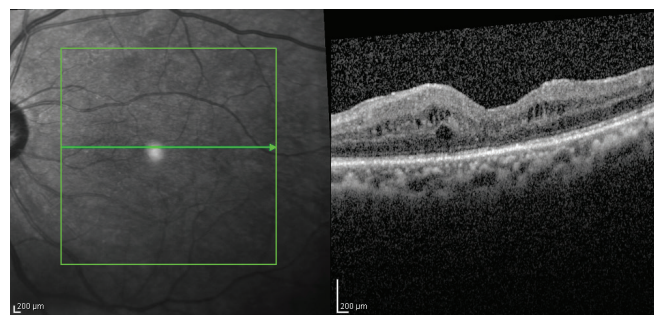


Figure 1. February 12, 2014 | left eye | 1 month prior to MicroPulse CST 340 μ m | VA 20/60.

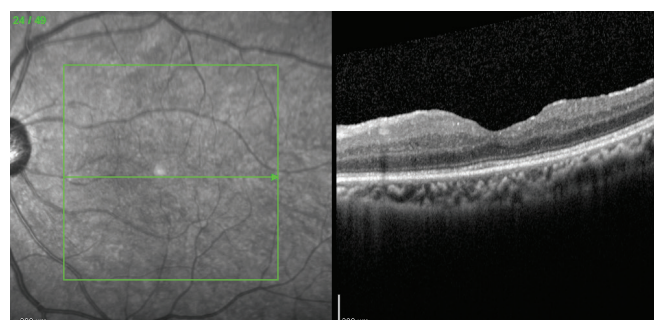


Figure 3. March 12, 2014 | left eye | 1 month post MicroPulse CST 280 μ m | VA 20/40 (baseline BCVA for this patient).

Table 1. TREATMENT PARAMETERS

- IQ 577 MicroPulse with TxCell for diabetic macular edema
- Wavelength: 577 nm
 - Spot size on slit lamp adapter: 200 μ m
 - Contact lens: Mainster (standard) focal/grid
 - Power: 300 mW (based on 2x the power determined from a continuous-wave test spot)
 - Exposure duration: 200 ms
 - Duty cycle: 5%
 - TxCell-Guided MicroPulse Delivery: High-density treatment in a grid pattern to blanket cover edematous area.

Treatment techniques and opinions presented in this case report are those of the author. IRIDEX assumes no responsibility for patient treatment and outcome. IRIDEX, IRIDEX logo are registered trademarks, MicroPulse, TxCell, and IQ 577 are trademarks of IRIDEX Corporation.