

Treatment Guidelines

Veterinary Procedures



IRIDEX



Glaucoma

Transscleral Diode Laser Protocol for Glaucoma

There are two transscleral diode laser protocols used for glaucoma treatment in dogs: higher power with shorter duration; and lower power with longer duration.

During treatment, both protocols create "pops" which are associated with boiling of intracellular water and aqueous. This indicates tissue disruption and reduced target protein coagulation. "Pops" may also increase post-operative inflammation.

Treatment Parameters

Higher Power/Shorter Duration

These parameters are from the original treatment protocol. About 50% of veterinarians who perform transscleral treatment for glaucoma are still using this protocol.

Case Classification (Dogs Only)

Prophylactic = IOP < 30 mm Hg: no clinical signs, fellow eye affected

Acute = IOP > 30 mm Hg: duration < 3 days, potentially visual

Chronic = IOP variable: +/- globe enlargement, +/- retinal atrophy, blind

Classification	Pre-op IOP	Sites	Joules X Sites
Prophylactic	<30 mm Hg	15-25	33.75-56.25
Acute & Chronic	>30 mm Hg	35-50	78.75-112.50

Power: 1500 mW

Duration: 1500 ms (2.25 J)

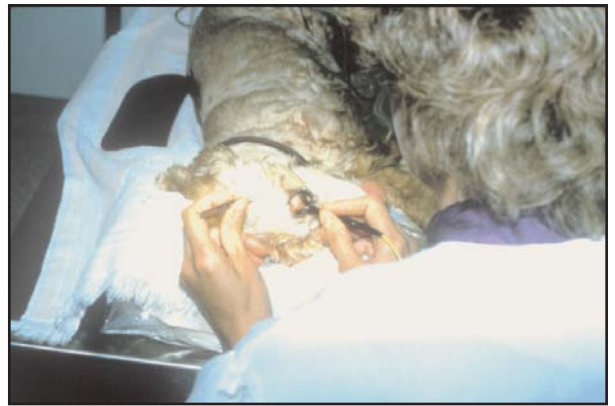Treatment sites: First five sites: (Lightly pigmented eyes may require more power.)

If no "pops", increase power to 1750 mW

If 2-3 "pops", maintain 1500 mW

If 4-5 "pops", decrease power until "pops" are heard in 50% to 75% of sites

"Pops" should be heard in 50% to 75% of treatment sites



Lower Power/Longer Duration

These parameters are thought to be a more gentle treatment alternative to higher power/shorter duration parameters, offering a greater potential for vision retention.

Power: 1000 mW

Duration: 4000 ms

Treatment sites: Visual eyes - 15 to 25; Blind eyes - 25 to 50

"Pops" should be heard in no more than 50% of the treatment sites

Treatment Guidelines

Pre-op: 0.5 mg/kg Banamine VI

Treatment: Avoid 3 o'clock and 9 o'clock positions

Avoid pigmentation in conjunctiva

Moisten the treatment sites with saline frequently

Superior limbus treated: First 20-30 sites superior-3 mm posterior to limbus

with consistent (.75-1.0 mm) indentation of sclera with probe held perpendicular

to sclera at each site, up to 3.5-4.0 mm if eye is buphthalmic. Next 15-20 sites

inferior-3 mm posterior to limbus with probe held perpendicular to sclera at each

site. Use measuring finger on probe for placement of 3 and 4 mm measurements.

Post-op: 4 mg tramcinolone subconjunctival

Topical antibiotic/steroid TID x 14 d

In 90% of cases, there is a pressure spike immediately post-treatment.

In visual eyes, this pressure must be relieved. Use a 30-gauge needle

paracentesis to bring the intraocular pressure (IOP) to 10 to 15 mm Hg.

Monitor the eye for several hours post-treatment, as multiple paracentesis

may be needed.



IRIDEX

Pigmented Tumors

Iris melanomas and limbal melanomas are the most common tumors treated with the diode laser. These tumors are always treated "to effect". Every tumor is different in size, thickness, and pigmentation. Thinner tumors normally don't require as much power or exposure duration as thicker tumors. Pigmentation also varies from animal to animal, so darker lesions will not require as much power as lighter lesions. The treatment with the laser should cause the tumor to "shrink". If there are tissue explosions, "popping" or smoke, the power is too high and must be lowered. If there is no reaction at all from the tumor, then the power should be increased.

Treatment Parameters for Pigmented Tumors

Using the Operating Microscope Adapter (OMA):

The best delivery device for tumors is the OMA. It provides precise control, great visualization, and a variety of spot sizes. The negative side of the OMA is that it only fits on Zeiss and Wild-style microscopes that are not that common in veterinary hospitals. When using the OMA, the spot size selected should be the largest to cover the area of the tumor. In many cases, this will be the 3.0 mm spot size. After the tumor has been thoroughly treated, a smaller spot size can be used around the edges.

Since the OMA is the only "large spot" (LS) delivery device capable of durations up to 10 minutes, other delivery devices must set the DURATION and INTERVAL settings to simulate the continuous delivery of laser energy. On all delivery devices except the OMA the DURATION should be set to 9000 ms and INTERVAL to 50 ms. This is as close to continuous-wave as is possible with the DioVet.

Since this is a "treatment-to-effect" procedure:

1. Set the power to 200 mW.
2. Set the duration to 5 minutes.
3. Select a spot size that fully encompasses the tumor.
4. Keep saline solution close by and irrigate the treatment area every 10-15 seconds to prevent corneal hazing and the heating of adjacent normal tissues.
5. Depress the footswitch and carefully watch the tumor. If shrinkage occurs, move the treatment beam slowly over the rest of the tumor either by using the joystick or moving the animal's head. If there is no reaction on the tumor surface increase the power by 200 mW and try again.
6. Shrinkage of the tumor should be immediate and easy to see.
7. Eventually, there will be a point that no more shrinkage is seen when irradiating with laser energy. Increase the power level by 200 mW and repeat step 5.
8. The time to stop treatment is usually when no more shrinkage is seen in the tumor or, in the case of iris melanoma, the pupillary margin will begin to stretch towards the tumor. This usually indicates that normal tissue is being constricted by the laser energy and the tumor has been thoroughly treated.
9. The tumor can be 30 to 50% of its original size after treatment. With iris melanomas, it is possible to get full-thickness necrosis in the lesion area several months after treatment. On very large tumors, more than one treatment may be necessary.

Other notes on tumors:

On limbal melanomas, it is recommended that the conjunctiva be folded back to fully expose the tumor. This allows direct exposure of the laser energy without any heat sinking or damaging effect to the conjunctiva.

Large limbal melanoma masses are much easier to treat if they are de-bulked first. De-bulk as much as possible and then irradiate the remaining areas.

Large limbal melanomas may extend into the iris and ciliary body. A combination of direct irradiation and transscleral cyclophotocoagulation is effective.

With a limbal melanoma, it is easy to "char" the surface of the tumor if it is not irrigated enough during treatment. If this happens, scrape the charred area with a scalpel to expose fresh tissue and continue treatment. Irrigate the treatment area more frequently.

If pigment is liberated and floating in the anterior chamber during treatment of an iris melanoma, monitor the animal for glaucoma due to tumor debris.

On very thick iris melanomas that are near the corneal surface, treat the sides and base of the tumor first to try and shrink it away from the cornea. If treated directly on the surface closest to the cornea, corneal hazing will result. This will inhibit visualization and laser delivery to the tumor. Slight corneal hazing is common and can be minimized with frequent saline irrigation. If corneal hazing becomes too intense, cease the treatment. It may be possible to repeat laser treatment several weeks to months later.

Pigmented Tumors

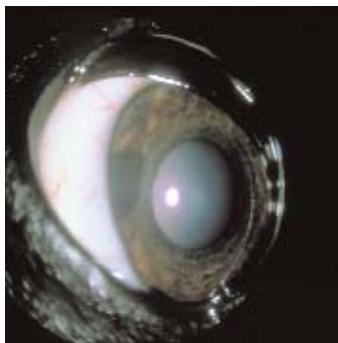
Treatment Parameters for Pigmented Tumors Using the Laser Indirect Ophthalmoscope (LIO):

The LIO is the next best option to the OMA. It is the most versatile tool because it can treat retinal disorders as well, but aligning the lesion to be treated with the examiner's view through the ophthalmoscope can be challenging. In most cases, the LIO is used without the 20D lens. This provides a 1.2 mm aerial image that works well for most tumors. If a larger spot size is needed, the surgeon can defocus the laser beam by moving closer or further away from the animal, but the same spot size must be maintained to achieve consistent energy density at the treatment site. Note: If the laser beam is moved back into focus, the energy density of the treatment site is increased and overtreatment may occur.

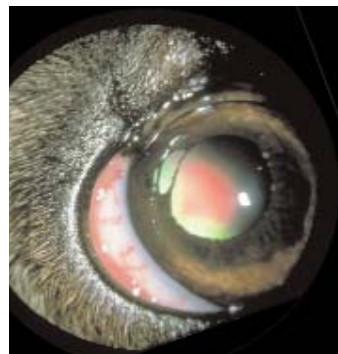
Since this is a "treatment-to-effect" procedure:

1. Set the power to 300 mW.
2. Set the duration to 9000 ms and the INTERVAL to 50 ms.
3. Do not use a focusing lens. Direct the beam of the LIO directly on the tumor. The spot size at focus is 1.2 mm.
4. Keep saline solution close by and irrigate the treatment area every 10-15 seconds to prevent corneal hazing and the heating of adjacent normal tissues.
5. Depress the footswitch and carefully watch the tumor. If shrinkage occurs, move the treatment beam slowly over the rest of the tumor either by using the joystick or moving the animal's head. If there is no reaction on the tumor surface, increase the power by 200 mW and try again.
6. Shrinkage of the tumor should be immediate and easy to see.
7. Eventually, there will be a point that no more shrinkage is seen when irradiating with laser energy. Increase the power level by 200 mW and repeat step 5.
8. The time to stop treatment is usually when no more shrinkage is seen in the tumor or, in the case of iris melanoma, the pupillary margin will begin to stretch towards the tumor. This usually indicates that normal tissue is being constricted by the laser energy and the tumor has been thoroughly treated.
9. The tumor can be expected to be 30 to 50% of its original size after treatment. With iris melanomas, it is possible to get full-thickness necrosis in the lesion area several months after treatment. On very large tumors, more than one treatment may be necessary.

Treatment with DioVet and Operating Microscope Adapter



Canine iris melanoma pre-op.



Canine iris melanoma six months post-op. Full thickness necrosis present.

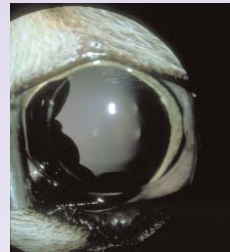Iris Cysts

Iris cysts are pigmented fluid-filled sacks in the anterior chamber that may be free-floating or attached to the iris. If the cysts become large enough or numerous enough, they may severely inhibit vision and eliminate IOP. The cysts are usually very thin-walled and, in many cases, the pigmentation is mottled. The laser indirect ophthalmoscope (LIO) or operating microscope adapter (OMA) can be used to rupture iris cysts.

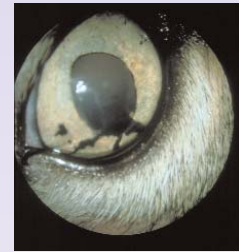Treatment Parameters Using the OMA and LIO

1. Set the power to maximum (OMA: 1200 mW; LIO: 1500 mW).
2. Set the duration to 100 ms.
3. Set the interval to 100 ms.
4. Select the 0.3 mm spot size.
5. Target the most heavily pigmented portion of the cyst. If the cyst is against the cornea, do not target the portion that is in contact with the cornea. Aim off to the side.
6. Depress the footswitch and carefully watch the cyst. If the cyst is well-pigmented, the surface should shrink and rupture, releasing the fluid. If it is a free-floating cyst it may be slowly propelled across the anterior chamber.
7. If there is no reaction, try an adjacent pigmented area and see if there is any reaction. Some cysts are so thin-walled that laser uptake may be difficult. Try and treat several locations with a longer duration. If the cyst walls can be made to shrink in several different areas, then the treated site may become dense enough to finally rupture.
8. Once the cyst ruptures, several more laser shots may be needed to ensure it collapses completely.

Treatment with DioVet and Laser Indirect Ophthalmoscope

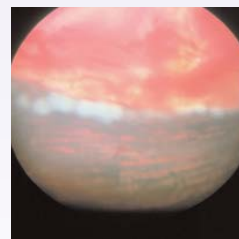


Feline iris cysts pre-op. Multiple large iris cysts causing anterior bowing of iris base and elevated IOP.



Feline iris cysts post-op. Resorbing cyst material present within anterior chamber.

Treatment with DioVet and DioPexy Probe



Seal of canine giant retinal tear with DioVet and DioPexy Probe (transscleral retinopexy)

Cysts

Other Retinal Pathologies

The EndoProbe®, LIO, and DioPexy™ probe can be used for the same types of retinal conditions seen in humans. Power levels vary greatly depending on the pigmentation of the animal. Heavily pigmented eyes may require as little as 200 mW, where light-eyed breeds like Huskies, may require more than one Watt to achieve a burn. If the fundus is too light, there will typically be no uptake.

Treatment over the tapetal area of the retina may require slightly more power.

Retinal Tears

Delivery Devices

	Iris Melanoma	Limbal Melanoma	Pigmented Skin Lesions	Iris Cysts	Retina	Xscl Glaucoma	Spot Size	Focal Point of Tip	Converging/ Diverging from Tip
Delivery Device									
Glaucoma Probe	No	No	No	No	No	Yes	600 μ m	~0	Diverging
OMA	Yes	Yes	Yes	Yes	Yes (1)	No	0.3, 0.5, 0.8, 1.2, 2 mm	6.88 in (with 175 mm objective lens)	Converging*
LIO	Yes	Yes	Yes	Yes (2)	Yes	No	400 μ m with 20D lens; 1200 μ m w/o lens	16 in. (406 μ m)	Converging*
DioPexy Probe	No	Yes (3)	Yes (3)	No	Yes	No	1000 μ m	1 mm	Collimated for 1 mm then diverging
EndoProbe	Yes	Yes (3)	Yes (3)	No	Yes	No	200 μ m	~0	Diverging, beam size 300 μ m at 1 mm

- (1) Limited treatment area
 (2) Will work on heavily pigmented cysts
 (3) Non-contact procedure

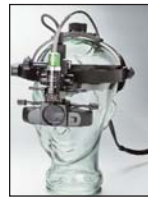*Only converging systems can be used for transcorneal treatment of intraocular tumors. With a diverging beam, the laser energy will be more concentrated nearer the probe tip; thus the cornea would be exposed to greater energy than the iris when a diverging beam is used transcorneally.



DioVet Laser System



Operating Microscope Adapter (OMA)



LIO



Glaucoma Probe



EndoProbe



DioPexy Probe

References

Cynthia Cook, DVM
 Veterinary Vision
 219 N. Amphlett Blvd.
 San Mateo, CA 94401
 650-342-4947

John Sapienza, DVM
 Long Island Veterinary Specialists
 163 South Service Road
 Plainview, NY 11803
 516-501-1700

Sam Vainisi, DVM
 Animal Eye Clinic
 5587 Highway 29
 Denmark, WI 54208
 920-863-3160



IRIDEX Corporation 1212 Terra Bella Avenue, Mountain View, CA 94043-1824 USA Phone: 650-962-8100 or 800-388-4747 (U.S. only) Fax: 650-962-0486
 Web: www.iridex.com

The IRIDEX logo is a registered trademark of IRIDEX Corporation.