

Treating DME with Fovea-Friendly Micropulse Laser Therapy

BY PATRICK CASKEY, MD

A 52-year-old male with a 25-year history of diabetes mellitus was referred to my office for evaluation in November 2011. Visual acuity was in the finger-counting range in the right eye and 20/50 in the left eye.

Examination of the right eye demonstrated proliferative diabetic retinopathy and a central retinal vein occlusion complicated by vitreous hemorrhage and neovascular glaucoma (Figures 1 and 2). The eye was treated with intravitreal bevacizumab (Genentech) and scheduled for vitrectomy.

The left eye demonstrated neovascularization of the disk and elsewhere; therefore, panretinal laser photocoagulation was performed at the initial visit. By June 2012, the neovascular activity had regressed completely but the patient's visual acuity had declined to 20/70 due to macular edema.

Spectral-domain optical coherence tomography (SD-OCT) scans were performed, revealing cystoid changes involving the perifoveal region, which had increased since 2011. The edema was diffuse in nature and involved the fovea, so the decision was made to perform focal micropulse laser therapy.

WHY MICROPULSE?

In the past, I treated diabetic macular edema (DME) with continuous-wave laser, very much as the Early Treatment Diabetic Retinopathy Study (ETDRS) guidelines recommended. However, I had never been particularly happy with that treatment protocol because of the retinal damage it produced and the risk implicit in using significant thermal energy levels adjacent to the fovea. Treatment within the fovea was out of the question, despite the fact that the most prominent edema was often found there.

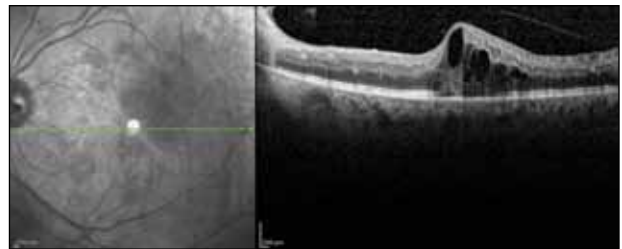


Figure 1. Cross-sectional OCT images prior to treatment showing cystoid macular edema in the left eye.

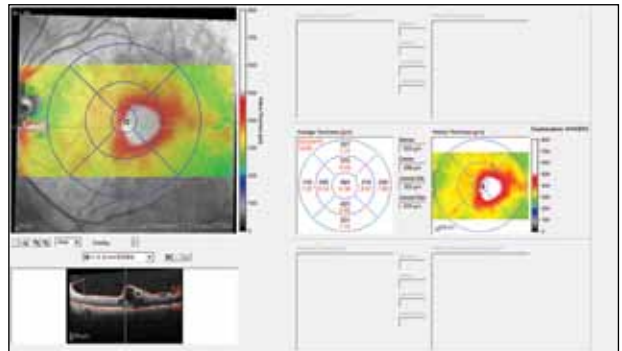


Figure 2. Macular thickness map prior to treatment.

Additionally, I found it unsettling that even the light ETDRS burns created at the time of treatment often evolved into larger, visually significant lesions over time. There are focal forms of DME associated with discrete microaneurysms which respond well to traditional treatment, but I typically see cases of DME that are more diffuse in nature, lacking a clearly-defined source of leakage and requiring extensive treatment coverage.

Micropulse technology finely controls thermal elevation by dividing a continuous-wave beam into a train of repetitive short pulses, allowing tissue to cool between pulses and thereby reducing thermal buildup.

Now, I rarely use continuous-wave focal treatment. For almost all of my patients, I employ micropulse using the IQ 577 laser (Iridex). Micropulse technology finely controls thermal elevation by dividing a continuous-wave beam into a train of repetitive short pulses, allowing tissue to cool between pulses and thereby reducing thermal buildup. Due to its limited thermal spread, micropulse treatment allows the administration of a greater number of treatment spots with denser spacing than is used for conventional laser grid treatments. With micropulse, we can treat this diffuse DME in a more active and effective way, without causing thermal damage.

In addition to new laser treatment modalities, the advent of SD-OCT provides physicians a better means of evaluating DME than past methods. Much of what may appear as active leakage on angiography turns out not to be when evaluated with OCT. In my experience, SD-OCT is more accurate in determining the levels of DME present, which facilitates better assessment of the effectiveness of treatment, especially in more diffuse and refractory forms of DME.

TREATMENT PARAMETERS

I treated the patient's left eye in July 2012 with a confluent pattern of 234 spots 100 μm in size, designed to cover the entire area of macular edema. Laser was applied at 200 ms duration at 160 mW of power with a 5% duty cycle. I adjusted the laser for an interval between treatments of 50 ms, which resulted in 4 treatment spots per second. This allowed me to move the aiming beam consistently through the area of edema in a defined fashion to facilitate a confluent treatment.

When the patient returned in September 2012, there was a significant reduction in DME, noted both clinically and on SD-OCT testing (Figures 3 and 4). His vision had improved somewhat, from 20/70 to 20/60-2. When seen again several weeks later, his vision had improved to 20/60.

SPECIAL CONSIDERATIONS

This was a Hispanic patient with a comparatively darkly pigmented iris and retina; the darker the pig-

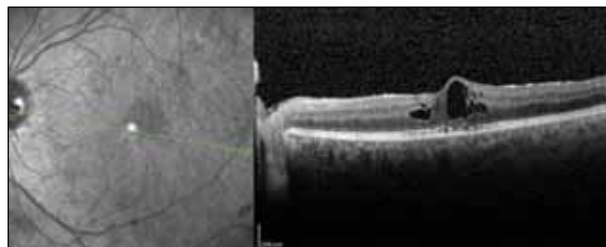


Figure 3. Cross-sectional scan of the left macula 2 months after treatment with micropulse laser therapy.

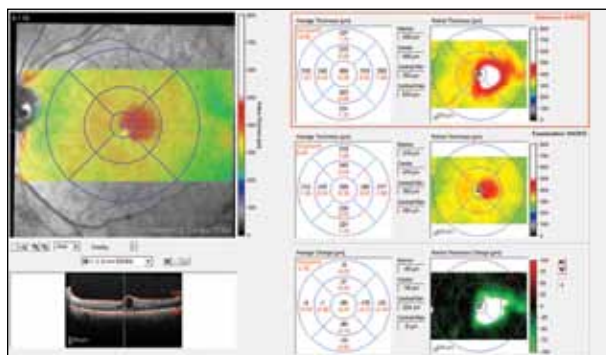


Figure 4. Macular thickness maps comparing pre- and 2 months post-treatment levels of macular edema.

ment, the more laser energy it tends to absorb for a given wattage. Thus, I used a power threshold reduced from what would be used for a patient with a more lightly pigmented fundus. During the transition to the use of micropulse, I found there was a learning period when I determined the parameters that worked best for me based on the experience of others. To become more comfortable with the concept of subthreshold treatment, it was a priority to establish a treatment algorithm that allowed confluent laser applications, and the combination of 200 ms spot duration with 50 ms intervals worked well for me.

ASSESSING THE OPTIONS

Another option for treating this patient would have been intravitreal injections of an anti-VEGF agent such as bevacizumab (Avastin, Genentech) or ranibizumab (Lucentis, Genentech). This was a situation, however, in which I needed to treat a relatively small but strategic amount of DME, and I felt that focal micropulse provided me with a better opportunity to treat in a specific and limited manner, rather than the less subtle process of an intravitreal injection. Also factored into the treatment decision was the small, but real, risk for infection and the limited treatment duration typically seen with an injection. We have found that within about 6 weeks following treatment with an intravitreal anti-VEGF

(Continued on page 84)

(Continued from page 80)

A relatively high percentage of patients treated with ongoing steroid injections will develop increased intraocular pressure, which may limit the use of this treatment over time.

agent, patients often revert back to their baseline edema and visual acuity levels, thus requiring additional injections. With focal micropulse, the treatment effect tends to last for at least several months and often significantly longer, and it does not preclude the option to use an injection as an adjunct later if necessary, or to repeat micropulse.

An injection of intravitreal steroid is another possibility I could have considered for this patient. However, a relatively high percentage of patients treated with ongoing steroid injections will develop increased intraocular pressure, which may limit the use of this treatment over time. As my experience with the various available therapeutic modalities has grown, I have found that I tend to use intravitreal steroids as a third-tier treatment, in cases in which focal micropulse or anti-VEGF agents are not adequate. My results with micropulse, either singly or in combination with anti-VEGF agents, have been sufficiently positive that I now use steroid injections infrequently.

CONCLUSION

Overall, I have found focal micropulse to be quite successful. Patients tolerate it well because there is no pain involved and, in comparison to continuous-wave laser, the micropulse laser flashes are more easily tolerated. Both the patient and the physician need to be aware that several treatment sessions over a period of 6 to 12 months may be required to reach optimal stability of the retina. Managing expectations is an important factor in treatment for DME, and I advise patients that the effects from focal micropulse develop over a period of 8 to 12 weeks. However, this gradual improvement tends to persist much longer than either anti-VEGF or steroid intervention, and additional micropulse typically improves the retinal status further. For these reasons, it has become my preferred option for DME. ■

Patrick Caskey, MD, practices with North Bay Vitreoretinal Consultants in Santa Rosa, CA. Dr. Caskey has no financial interests to disclose. He may be reached at pcaskey@sonic.net.

