

## Original Article

# Micropulse transscleral diode laser cyclophotocoagulation in the treatment of refractory glaucoma

Anna M Tan FAMS,<sup>1</sup> Muthuraman Chockalingam FRCS,<sup>2</sup> Maria C Aquino MD,<sup>1</sup> Zena I-L Lim FRCS,<sup>3</sup> Jovina L-S See FRCS<sup>1</sup> and Paul TK Chew FRCS<sup>1</sup>

<sup>1</sup>Department of Ophthalmology, National University Hospital, <sup>2</sup>Uma Eye Clinic, Chennai, India, and <sup>3</sup>Singapore National Eye Centre, Singapore

## Abstract

**Background:** Transscleral diode laser cyclophotocoagulation (TSCPC) is an established method of treatment for refractory glaucoma, but is associated with significant complications. This study evaluates the efficacy and safety of a new form of TSCPC using micropulse diode laser and trans-pars plana treatment with a novel contact probe.

**Methods:** Prospective interventional case series of 40 eyes of 38 consecutive patients with refractory glaucoma treated with micropulse TSCPC with a novel probe. Outcomes measured were success, hypotony and response rates.

**Results:** The mean age of patients was  $63.2 \pm 16.0$  years. The mean follow-up period was  $16.3 \pm 4.5$  months. The mean intraocular pressure (IOP) before micropulse TSCPC was  $39.3 \pm 12.6$  mmHg. Mean IOP decreased to  $31.1 \pm 13.4$  mmHg at 1 day,  $28.0 \pm 12.0$  mmHg at 1 week,  $27.4 \pm 12.7$  mmHg at 1 month,  $27.1 \pm 13.6$  mmHg at 3 months,  $25.8 \pm 14.5$  mmHg at 6 months,  $26.6 \pm 14.7$  mmHg at 12 months and  $26.2 \pm 14.3$  mmHg at 18 months ( $P < 0.001$  at all time points). No patient had hypotony or loss of best-corrected visual acuity. The overall success rate after a mean of 1.3 treatment sessions was 72.7%.

**Conclusion:** Micropulse TSCPC is a safe and effective method of lowering IOP in cases of refractory glau-

coma and is comparable with conventional TSCPC.

**Key words:** micropulse laser, refractory glaucoma, transscleral diode cyclophotocoagulation, trans-pars plana.

## INTRODUCTION

Glaucoma is a leading cause of irreversible blindness worldwide.<sup>1</sup> When intraocular pressure (IOP) is difficult to control with medications, surgical intervention is required to preserve optic nerve function.<sup>2</sup> Primary surgical procedures include trabeculectomy with or without anti-metabolites, as well as glaucoma drainage implants.<sup>2–4</sup> Cycloablation lowers IOP by destruction of ciliary body epithelium and stroma, thus reducing aqueous production.<sup>5,6</sup> Cycloablation using cryotherapy was associated with high risk of vision-threatening complications.<sup>7,8</sup> Diode laser cyclophotocoagulation appeared safer than cyclocryotherapy although complications still occur.<sup>8–17</sup>

Diode laser micro pulsing has been shown in previous clinical and experimental studies to be useful in achieving targeted tissue damage and minimizing collateral thermal injury to adjacent tissues.<sup>18–25</sup> In contrast to conventional laser delivery where a continuous train of high intensity energy is delivered, micropulse laser application delivers a series of repetitive short pulses of energy with rest periods in between pulses. This has been used successfully in diode laser photocoagulation for the treatment of retina diseases.<sup>18–23</sup>

■ **Correspondence:** Dr Anna M Tan, Department of Ophthalmology, National University Hospital, 5 Lower Kent Ridge Road, 119074, Singapore. Email: amwttan@yahoo.com

Received 10 June 2009; accepted 3 November 2009.

© 2010 The Authors

Journal compilation © 2010 Royal Australian and New Zealand College of Ophthalmologists

Micropulsing diode laser contact transscleral cyclophotocoagulation (DLTSC) has been tried in the treatment of refractory glaucoma. In a previous study, 810 nm infrared diode laser radiation in the micropulse mode was used in conjunction with a G probe (Iris Medical Instruments, Mountain View, CA, USA).<sup>26</sup> In another pilot study, DLTSC was modified to target the pars plana region *ab externo* using a specially designed probe in which the diode laser emitting fibre optic was positioned more posteriorly from the limbus as compared with a G probe.<sup>27</sup> This modification led to a significant reduction in IOP in the majority of patients at 1 week, with less but still significant effect at 12 weeks.

The authors conducted this prospective non-comparative study combining the usage of this novel contact probe with micropulse diode laser settings in eyes with refractory glaucoma.

## METHODS

This is a prospective, non-comparative interventional case series of consecutive consenting patients diagnosed with refractory glaucoma at the National University Hospital, Singapore, were recruited between May 2006 and December 2006.

The diagnostic and inclusion criteria were:

- Patients with refractory glaucoma, defined as IOP > 21 mmHg on maximal tolerated medical therapy with or without prior glaucoma surgical procedures
- Patients who refuse or are poor candidates for additional filtering surgery or implantation of glaucoma drainage devices
- A best-corrected visual acuity of worse than 6/60 on Snellen chart testing
- A minimum follow-up of 12 months

The following patients were excluded from the study:

- Patients who had undergone any intraocular surgery within 2 months of enrolment
- Patients unable to give informed consent
- Patients who had undergone previous conventional transscleral diode laser cyclophotocoagulation (TSCPC)
- Patients with significant scleral thinning defined as thinning of more than one clock hour noticed on scleral transillumination
- Patients who refused re-treatment for better IOP control after failure of the first sitting

The micropulse TSCPC procedure was performed by a single surgeon in the outpatient setting. Peribulbar anaesthesia of 3–5 mL of 2% ligno-

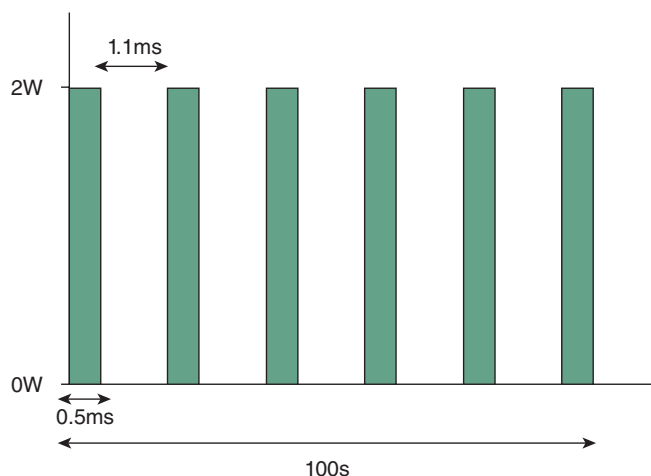


**Figure 1.** New contact probe for micropulse transscleral cyclophotocoagulation.

caine hydrochloride 100 mg/5 mL (AstraZeneca, Singapore Pte Ltd) was given before the procedure. Scleral transillumination was used to identify any areas of thinning, and a diode laser emitting ball-lens tip contact probe was applied perpendicular to the limbus. This probe houses a quartz fibre optic of 600 µm in diameter, with its hemispherical tip protruding 0.7 mm from the hand piece. The probe was designed to allow for accurate positioning of the fibre-optic tip at 3 mm posterior to the limbus (Fig. 1).

The laser settings (Fig. 2) used were 2000 mW of 810 nm infrared diode laser radiation set on micropulse mode (Iris Medical Instruments, Mountain View, CA, USA), delivered over 100 s (envelope of micropulses). This translates to a total of 62 500 micropulses delivered with 0.5 ms on and 1.1 ms off time (duty factor of 31.3%). A total energy of 62.6 J was thus delivered to each eye.

The probe was applied with firm pressure and moved in a continuous sliding arc motion to and fro ('painting') from 9:30 o'clock to 2:30 o'clock for the superior quadrant for 50 s, and from 3:30 o'clock to 8:30 o'clock for the inferior quadrant for another 50 s. The 3 and 9 o'clock meridians were spared, along with any area of thinned sclera. In some cases



**Figure 2.** Settings for laser delivery.

**Table 1.** Postoperative record of pain on a verbal analogue scale

Pain grade	Description of pain
None	No subjective feeling of pain
Mild	Pain tolerable and not requiring use of oral analgesia
Moderate	Pain tolerable with regular usage of oral analgesia
Severe	Pain despite regular dosing of oral analgesia

where the conjunctiva was loose, laser treatment was stopped momentarily to release any caught conjunctiva before reapplication of the probe at the same spot and continuation of the treatment.

The amount of intraoperative pain experienced by the patient was recorded and additional peribulbar anaesthesia was administered as required. Postoperatively, topical prednisolone acetate 1% (Pred Forte, Allergan Pte Ltd, Singapore) was prescribed four times daily for a minimum of 1 week and then tapered depending on the anterior chamber reaction. All pre-procedure glaucoma medications were continued.

Follow-up examinations were performed at 1 day, 1 week, 1 month, 3 months, 6 months, 12 months and 18 months. Pain scoring on a verbal analogue scale (Table 1), best-corrected visual acuity, IOP, number and type of tolerable medications required to maintain an IOP of 21 mmHg or 30% reduction from baseline, detailed anterior segment examination including corneal clarity, anterior chamber reaction, gonioscopic findings and optic nerve head examination, were recorded preoperatively, and then again at each follow-up visit. The IOP was measured using the Goldmann Applanation Tonometer. The mean of two measurements with a time interval of 5 min was taken.

**Table 2.** Distribution of glaucoma diagnoses

Type of glaucoma	n (%)
Neovascular glaucoma	16 (40.0)
Primary open angle glaucoma	9 (22.5)
Primary angle closure glaucoma	10 (25.0)
Aphakic glaucoma	2 (5.0)
Silicone oil induced glaucoma	2 (5.0)
Juvenile glaucoma	1 (2.5)

The anti-glaucoma medications were adjusted and when a pressure lowering effect was observed; medical therapy was reduced in a stepwise fashion, starting with oral acetazolamide. We waited for a minimum of 1 month for the full IOP lowering effect of the first micropulse DLTSC to stabilize. After 1 month, if the IOP reduction was less than 30% from baseline on two consecutive visits separated by an interval of at least 1 week, retreatment was performed. The settings were similar to the first treatment, except for an increase in the pulse envelope to 160 s. This results in a standard delivery of 100 J of energy to each eye.

In this study, relative success was defined as maintaining IOP of 6–21 mmHg or achieving 30% or more reduction in IOP from baseline, with or without topical IOP lowering medications, at final follow-up. The need for a repeat micropulse DLTSC was not considered a failure. The outcome of the therapy was defined in terms of success rate, hypotony rates, response rates (success and hypotony rates considered together) and re-treatment rates.

Statistical analysis was performed using SPSS software version 15.0 (SPSS Inc., Chicago, IL, USA). Parameters were compared using the paired *t*-test; a *P*-value < 0.05 was considered significant.

## RESULTS

Forty eyes of 38 patients were recruited in the study and received micropulse DLTSC between May 2006 and December 2006. Table 2 summarizes the types of glaucoma treated with micropulse DLTSC.

There were 30 males (78.9%) and 8 females (21.1%). Right eye of 15 patients (37.5%) and left eye of 21 (52.5%) and both eyes of two patients underwent treatment with micropulse DLTSC. The mean  $\pm$  standard deviation (SD) laser energy delivered per eye was  $97.6 \pm 48.4$  J of the 40 eyes treated, 14 eyes (35.0%) required a second sitting of micropulse DLTSC between 4 and 12 weeks after initial treatment. No eye received a third treatment. A total of 54 treatment sessions were carried out in these 40 eyes with a mean of 1.4 sessions per eye.

The follow-up ranged from 12 to 18 months after micropulse DLTSC. The mean  $\pm$  SD follow-up period was  $17.3 \pm 2.0$  months.

Rate of relative success, defined as either maintaining an IOP of less than 21 mmHg or achieving a reduction of 30% from baseline IOP with or without supplementing topical anti-glaucoma medications was 80% (32 out of 40 eyes) at final follow-up. None of the eyes required systemic IOP lowering medications. The mean  $\pm$  SD pre-treatment IOP was  $40.1 \pm 11.6$  (range 21–70) mmHg. The mean  $\pm$  SD post treatment IOP was  $31.1 \pm 13.4$  mmHg on post-operative day 1 (range 9–55 mmHg),  $27.4 \pm 12.7$  mmHg at 1 month follow-up (range 9–50 mmHg),

$25.8 \pm 14.5$  mmHg at 6 months follow-up (range 6–46 mmHg),  $24.7 \pm 10.8$  at 12 months follow-up (range 10–50 mmHg) and  $24.6 \pm 9.6$  mmHg at final follow-up (range 12–52 mmHg).

The mean IOP on day 1 post treatment, the mean at 1 year and the mean IOP at final follow-up, were all statistically lower than the pre-treatment IOP ( $P < 0.001$ , paired *t*-test). There were no cases of hypotony, defined as IOP less than 6 mmHg, at final follow-up. Table 3 summarizes the IOP of these 40 eyes at various points of follow-up.

**Table 3.** IOP before and after micropulse diode transcleral cyclophotocoagulation

Patient	Sex	Age (years)	IOP before laser (mmHg)	IOP at 12 months (mmHg)	IOP at final follow-up (mmHg)
1	F	13	40	22	20
2	M	88	34	10	15
3	M	71	30	24	20
3 <sup>†</sup>	M	71	23	17	16
4	M	26	30	20	20
5	M	53	35	16	19
6	M	70	26	11	12
7	M	45	24	19	18
8	M	78	45	17	14
9	M	72	38	20	19
10	M	50	66	10	14
11	M	66	42	16	16
12	M	58	70	12	18
13	M	72	24	15	19
14	F	67	52	10	15
15	M	65	21	12	12
16	F	62	24	16	18
17	M	67	36	23	22
18	M	36	34	30	24
18 <sup>‡</sup>	M	36	36	21	23
19	M	91	40	24	28
20	M	76	40	26	28
21	F	70	37	18	24
22	M	78	55	36	32
23	F	78	49	34	26
24	M	51	58	46	40
25	M	70	55	28	30
26	M	63	40	23	23
27	M	72	38	30	28
28	F	76	38	30	23
29	M	68	32	22	22
30	F	38	54	50	44
31	M	45	42	30	36
32	M	57	38	34	30
33	M	78	45	40	45
34	M	72	38	30	28
35	M	50	54	48	52
36	F	84	47	47	45
37	M	50	48	20	23
38	M	72	25	30	24
Mean $\pm$ SD		$62.6 \pm 16.8$	$40.1 \pm 11.6$	$24.7 \pm 10.8$	$24.6 \pm 9.6$
P value*		NA	NA	<0.001	<0.001

\*Paired *t*-test, as compared to pre-cyclophotocoagulation levels. <sup>†</sup>Second eye of patient 3. <sup>‡</sup>Second eye of patient 18. F, female; FU, follow-up; IOP, intraocular pressure; M, male; SD, standard deviation.

The mean  $\pm$  SD of IOP lowering medications was reduced from  $2.1 \pm 1.1$  (range, 0–4) before cyclophotocoagulation to  $1.3 \pm 1.0$  (range, 0–3) at final follow-up ( $P < 0.001$  when compared with preoperative level, paired *t*-test). All six patients who required systemic acetazolamide preoperatively were able to stop the medication on day 1 after laser.

The pre-treatment visual acuity ranged from no light perception to 6/60. Improved vision is defined as one or more Snellen line gain or change from light perception to perception of hand movement. Deterioration in vision is defined as Snellen fall off of one or more line. Visual acuity improved from pre-micropulse DLTSC to final follow-up in 4 of 40 eyes (10%) and remained unchanged in 36 of 40 eyes (90%). None of the patients had deterioration of their best-corrected visual acuity at final follow-up visit.

During the procedure, a total of 12 patients (31.6%) reported experiencing pain; 10 (26.3%) had tolerable pain that did not require any additional anaesthesia. Two patients (5.3%) required additional regional anaesthesia. Post procedure, seven patients (18.4%) reported mild pain on the first day. None experienced moderate or severe pain. All the eight patients with a painful blind eye expressed relief of their eye symptoms after the procedure. All patients had mild postoperative inflammation at day 1 in the form of 1+ anterior chamber cells with slight conjunctival hyperaemia. This resolved by 2-week post-treatment in 36 eyes (90%). In the remaining four eyes (10%), the uveitis resolved in 4 weeks' time. Seven eyes (17.5%) developed hyphaema post laser, all of which were in patients with neovascular glaucoma. There were no cases of scleral perforation, phthisis bulbi, endophthalmitis or sympathetic ophthalmia. One patient who had no light perception before micropulse TSCPC underwent evisceration at 6 weeks for corneal perforation secondary to infection on pre-existing bullous keratopathy.

The success rate was 80% (32 out of 40 eyes) for the entire study period. After adjustment for diagnoses, the highest failure rate was observed in patients with neovascular glaucoma (6 out of 12 eyes). However, due to the small numbers, univariate and multivariate models of logistic regression analysis did not identify any predictors of failure (e.g. age, sex, type of glaucoma diagnoses, pre-treatment IOP) in this study.

As there were no cases of hypotony during any of the follow-up visits, the response rate was similar to success rate. 65% (26 out of 40 eyes) achieved a successful IOP control after one treatment. A further 15% (6 eyes) gained success after two treatments. Nine eyes (20%) had unsatisfactory IOP control after two treatments. The overall failure rate, including the eye that was eviscerated, was 20%.

## DISCUSSION

In this study, the rate of relative success, defined as either maintaining an IOP of less than 21 mmHg or achieving a reduction of 30% from baseline IOP with or without topical anti-glaucoma medications was 80% at final follow-up. Mean IOP was significantly reduced from the preoperative mean  $\pm$  SD of  $40.1 \pm 11.6$  mmHg to  $24.6 \pm 9.6$  at final follow-up ( $P < 0.001$ ); and there was no statistical difference between mean IOP at 12 months ( $24.7 \pm 10.8$ ) and at final follow-up ( $P = 0.37$ ). The mean  $\pm$  SD of IOP lowering medications was reduced from  $2.1 \pm 1.1$  (range, 0–4) before micropulse DLTSC to  $1.3 \pm 1.0$  (range, 0–3) at final follow-up ( $P < 0.001$ , paired *t*-test).

Diode laser TSCPC targets pigmented intraocular tissues, including that of the ciliary body epithelium. Conceptually, micropulse application of laser allows energy to build up with each subsequent pulse to result in photocoagulation, whereas adjacent non-pigmented tissue cools during the off-cycle and remains below its coagulation threshold. Several investigators have described their clinical studies utilizing diode laser micropulsing.<sup>18–25</sup> Parodi *et al.* found the efficacy of sub-threshold grid laser treatment with micropulse diode laser to be comparable with that of threshold grid laser treatment for macular oedema secondary to branch retinal vein occlusion despite the lack of biomicroscopic and angiographic signs.<sup>19</sup> Laursen *et al.* showed that micropulse diode laser had a stabilizing or even improving effect on diabetic macular oedema.<sup>21</sup>

Traditionally cyclodestructive procedures, including cyclocryotherapy and cyclophotocoagulation, were reserved for eyes with refractory glaucoma and limited visual prognosis. The reason for cyclodestructive procedures not being accepted widely as a primary procedure in seeing eyes was that earlier studies indicated significant complications. Cyclodestruction using laser turned out to be safer, but complications may include vision loss, corneal oedema, pupillary distortion, cystoid macular oedema and hypotony. Theoretically, thermal localization with micropulse diode laser TSCPC offers the possibility of minimizing collateral tissue damage, and hence avoiding the pronounced tissue disruption of ciliary body, epithelium and ciliary processes seen in histological specimens after conventional TSCPC.<sup>28</sup> This may explain the lack of severe complications such as hypotony, loss of vision and phthisis bulbi in this study. The procedure appears to be well tolerated by patients both during as well as after the laser session and abolishes the need for overnight patching or use of cycloplegic agents.

During the procedure, a total of 12 patients (31.6%) reported experiencing pain out of which

only two patients (5.3%) required additional regional anaesthesia. None experienced moderate or severe pain. Micropulse application may be less painful by limiting thermal diffusion to sensory neurons in the deep choroid. Friberg and Venkatesh compared the pain associated with diode laser photocoagulation using a continuous delivery mode with that of micropulse settings and found that most patients experienced less pain with the micropulse mode.<sup>29</sup> Another possible explanation for the treatment being less painful was the fact that the absolute amount of energy delivered was less compared to traditional TSCPC.

The rapidity of IOP reduction, seen as early as 1 day post treatment, is a possible additional advantage over conventional TSCPC. The rapid reduction in IOP seen may be due to enhanced uveoscleral outflow. Two experimental studies have reported increased uveoscleral aqueous outflow after transscleral laser treatment centred over the pars plana. The first, by Schubert *et al.* on post-mortem human eyes and on porcine eyes, found that the outflow increase was directly proportional to the surface area treated with laser.<sup>30</sup> The second, performed by Liu *et al.* on monkey eyes, used tracer particles to provide evidence that the IOP reduction produced by the laser treatment over the pars plana results from the enhancement of uveoscleral outflow.<sup>31</sup> One may, however, postulate that the IOP-lowering effect was secondary to inflammation, which in turn may lead to decreased aqueous production and/or increasing uveoscleral outflow. This should result in only a transient reduction in IOP that disappears as the inflammation settles. This study, however, shows the sustainability of IOP reduction even after inflammation had settled clinically.

Like other micropulse laser protocols, the protocol that was used has no clinically evident end point (e.g. 'pops' heard in conventional TSCPC) to help titrate or confirm therapy. It is hence difficult to know when treatment is adequate for individual patients. As the contact probe is applied in a standard fashion with the laser emitting fibre-optic tip located precisely at 3 mm posterior to the limbus, transillumination to localize the position of the ciliary body band is not routinely performed. This, however, leads to the question of which structure or process the laser is exerting an effect on, especially in cases where the ciliary body location is uncertain. Nonetheless, this descriptive study has demonstrated the IOP lowering efficacy of this novel method of micropulse TSCPC up to 18 months.

To conclude, micro pulse diode TSCPC appears to be a promising, safe alternative procedure with potential advantages like minimizing further the complications as compared to conventional diode

TSCPC. This non-comparative case series is limited by a small sample size and relatively brief follow-up. Longer follow-up is required to determine the longevity of the treatment effect and rate of late complications. The treatment protocol needs further evaluation in multicenter studies to assess the reproducibility of results. Histological specimens of eyes treated with micropulse TSCPC are required to study its biological effects on the ciliary epithelium and processes. Ultimately, a randomized controlled trial comparing conventional TSCPC with this new method of micropulse TSCPC will provide more data on the role of micropulse TSCPC for the treatment of patients with refractory glaucoma.

### ACKNOWLEDGEMENT

The authors would like to acknowledge Dr YH Chan, Head, Biostatistics Unit, Yong Loo Lin School of Medicine, for his valuable assistance in statistical analysis.

### REFERENCES

1. Quigley HA, Broman AT. The number of people with glaucoma worldwide in 2010 and 2020. *Br J Ophthalmol* 2006; **3**: 262–7.
2. Lai JS, Tham CC, Lam DS. Surgical management of chronic closed angle glaucoma. *Asian Pac J Ophthalmol* 2003; **15**: 5–10.
3. Nouri-Mahdavi K, Brigatti L, Weitzman M, Caprioli J. Outcomes of trabeculectomy for primary open-angle glaucoma. *Ophthalmology* 1995; **102**: 1760–9.
4. Nguyen QH. Primary surgical management refractory glaucoma: tubes as initial surgery. *Curr Opin Ophthalmol* 2009; **20**: 122–5.
5. Feldmann RM, El-Harazi SM, LoRusso FJ, McCash CE, Lloyd WC 3rd, Warner PA. Histopathologic findings following contact transscleral semiconductor diode laser cyclophotocoagulation in a human eye. *J Glaucoma* 1997; **2**: 139–40.
6. Noecker RJ, Kelly T, Patterson E, Herrygers LA. Diode laser contact transscleral cyclophotocoagulation: getting the most from the G – probe. *Ophthalmic Surg Lasers Imaging* 2004; **35**: 124–30.
7. Benson MT, Nelson ME. Cyclocryotherapy: a review of cases over 10 years period. *Br J Ophthalmol* 1990; **7**: 103–5.
8. Caprioli J, Strang SL, Speath GL, Poryzees EH. Cyclocryotherapy in the treatment of advanced glaucoma. *Ophthalmology* 1985; **92**: 947–54.
9. Bloom PA, Tsai JC, Sharma K *et al.* 'Cyclodiode'. Transscleral diode laser cyclophotocoagulation in the treatment of advanced refractory glaucoma. *Ophthalmology* 1997; **104**: 1508–19.
10. Guptha N, Weinreb RN. Diode laser transscleral cyclophotocoagulation. *J Glaucoma* 1997; **6**: 426–9.
11. Izgi B, Demirci H, Demirci FY, Turker G. Diode laser cyclophotocoagulation in refractory glaucoma;

- comparison between pediatric and adult glaucomas. *Ophthalmic Surg Lasers* 2001; **32**: 100–7.
12. Kosoko O, Gaasterland DE, Pollack IP, Enger CL. Long term outcome of initial cycloablation with contact diode laser transscleral cyclophotocoagulation for severe glaucoma. The Diode Laser Ciliary Ablation Study Group. *Ophthalmology* 1996; **103**: 1294–302.
  13. Mistberger A, Liebmann JM, Tschiderer H, Ritch R, Ruckhofer J, Grabner G. Diode laser transscleral cyclophotocoagulation for refractory glaucoma. *J Glaucoma* 2001; **10**: 288–93.
  14. Schlote T, Derse M, Zierhut M. Transscleral diode laser cyclophotocoagulation for the treatment of refractory glaucoma secondary to inflammatory eye disease. *Br J Ophthalmol* 2000; **84**: 999–1003.
  15. Threlked AB, Johnson MH. Contact Transscleral diode cyclophotocoagulation for refractory glaucoma. *J Glaucoma* 1999; **8**: 3–7.
  16. Yap-Veloso MI, Simmons RB, Echelman DA, Gonzales TK, Veira WJ, Simmons RJ. Intraocular pressure control after contact transscleral contact diode laser cyclophotocoagulation in eyes with intractable glaucoma. *J Glaucoma* 1998; **7**: 319–28.
  17. Lai JS, Tham CC, Lam DS. Pupillary distortion and staphyloma following transscleral contact diode cyclophotocoagulation: a clinicopathological study of three patients. *Eye* 2002; **16**: 674.
  18. Sivaprasad S, Sandhu R, Tandon A, Sayed-Ahmed K, McHugh DA. Subthreshold micropulse diode laser photocoagulation for clinically significant diabetic macular oedema: a three-year follow up. *Clin Experiment Ophthalmol* 2007; **35**: 640–4.
  19. Parodi MB, Spasse S, Iacono P, Di Stefano G, Canziani T, Ravalico G. Subthreshold grid laser treatment of macular edema secondary to branch retinal vein occlusion with micropulse infrared (810 nanometer) diode laser. *Ophthalmology* 2006; **113**: 2237–42.
  20. Desmetre TJ, Mordon SR, Buzawa DM, Mainster MA. Micropulse and continuous wave diode retinal photocoagulation: visible and subvisible lesion parameters. *Br J Ophthalmol* 2006; **90**: 709–12.
  21. Laursen ML, Moeller F, Sander B, Sjeolie AK. Sub-threshold micropulse diode laser treatment in diabetic macular oedema. *Br J Ophthalmol* 2004; **88**: 1173–9.
  22. Moorman CM, Hamilton AM. Clinical applications of the micropulse diode laser. *Eye* 1999; **13**: 145–50.
  23. Pollack JS, Kim JE, Pulido JS, Burke JM. Tissue effects of subclinical diode laser treatment of the retina. *Arch Ophthalmol* 1998; **116**: 1633–9.
  24. Berger JW. Thermal modeling of micropulsed diode laser retinal photocoagulation. *Lasers Surg Med* 1997; **20**: 409–15.
  25. Chong LP, Kelsoe W, Donovan D. Selective RPE damage by micropulsed diode laser photocoagulation. *Invest Ophthalmol Vis Sci* 1992; **33**: 722.
  26. Ho CL, Wong EY, Chew PT. Effect of diode laser transscleral pars plana photocoagulation on intraocular pressure in glaucoma. *Clin Exp Ophthalmol* 2002; **30**: 343–7.
  27. Ho CL. Micropulse diode transscleral cyclophotocoagulation. *Asian J Ophthalmol* 2002; nos 3,4, 2001 Supplement.
  28. Pantcheva MB, Kahook MY, Schuman JS, Rubin MW, Noecker RJ. Comparison of acute structural and histopathological changes of the porcine ciliary processes after endoscopic cyclophotocoagulation and transscleral cyclophotocoagulation. *Clin Experiment Ophthalmol* 2007; **35**: 270–4.
  29. Friberg TR, Venkatesh S. Alteration of pulse configuration affects the pain response during diode laser photocoagulation. *Lasers Surg Med* 1995; **16**: 380–3.
  30. Schubert HD, Agarwala A. Quantitative CW Nd:YAG pars plana transscleral photocoagulation in postmortem eyes. *Ophthalmic Surg* 1990; **21**: 835–9.
  31. Liu GJ, Mizukawa A, Okisaka S. Mechanism of intraocular pressure decrease after contact transscleral continuous-wave Nd:YAG laser cyclophotocoagulation. *Ophthalmic Res* 1994; **26**: 65–79.