

MicroPulse® Monotherapy Effective for Patient with Bilateral CSR in First Trimester of Pregnancy



Karen Barraza Lino, MD, is a vitreoretinal specialist at Oftalmosalud & Clínica Internacional in Lima, Peru.



Daniela Rodríguez Mesías, MD, is a retina fellow at Oftalmosalud & Clínica Internacional in Lima, Peru.

Central serous chorioretinopathy (CSR) is characterized by temporary loss of visual acuity caused by leakage of the choriocapillaris. The leakage leads to fluid build-up under the retinal pigment epithelium (RPE) and detachment of the neurosensory retina. In 60% to 70% of cases, CSR resolves without treatment in 3 to 6 months.¹ In some cases, the subretinal fluid persists and requires intervention to restore visual function and prevent progressive RPE atrophy and permanent vision loss.² When the leak source can be identified by fluorescein angiography (FA), CSR can be treated with continuous-wave (CW) argon laser. However, this is avoided if the leak is near the fovea due to the propensity of the laser to cause scarring and scotoma. Reduced fluence photodynamic therapy (PDT) and anti-VEGF injections

also are options for treating CSR, but for our patient who was pregnant, none of these potential therapies were appropriate. MicroPulse laser therapy — given its high safety profile — was the ideal treatment choice, and was very successful.

MICROPULSE IS AN EFFECTIVE TREATMENT SOLUTION

At 8 weeks pregnant, our 29-year-old patient told us she was experiencing difficulty with vision in her right eye. Her best-corrected visual acuity (BCVA) was 20/40 in that eye and 20/20 in the left eye, and optical coherence tomography (OCT) revealed a neurosensory retina detachment OD. We decided to monitor her monthly.

Thirteen weeks into our patient's pregnancy, the neurosensory retina detachment OD measured 413 μm in height and 5,660 μm in width, and BCVA deteriorated to 20/100 (**Figure 1**). OCT also revealed RPE changes OD and a neurosensory retina detachment OS, which was 219 μm in height and 3,181 μm in width, with no changes in the RPE (**Figure 2**). BCVA OS was 20/40. The patient denied taking steroids, which can induce CSR.

We referred her to a gynecologist to rule out preeclampsia and antiphospholipid antibody syndrome, both dangerous systemic conditions that have been

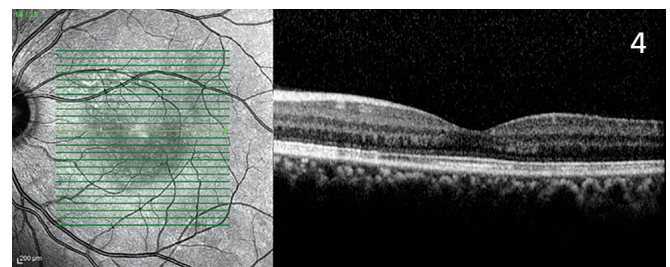
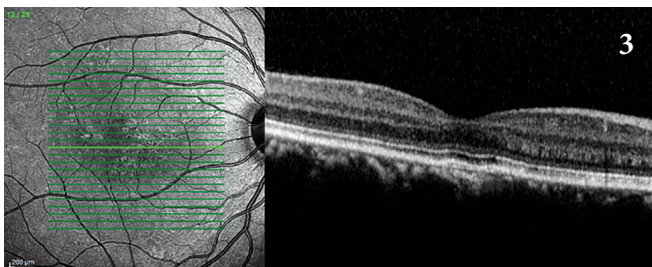
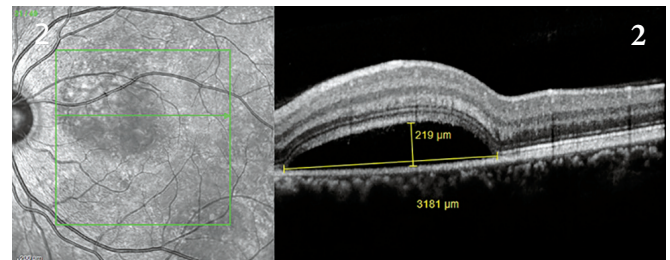
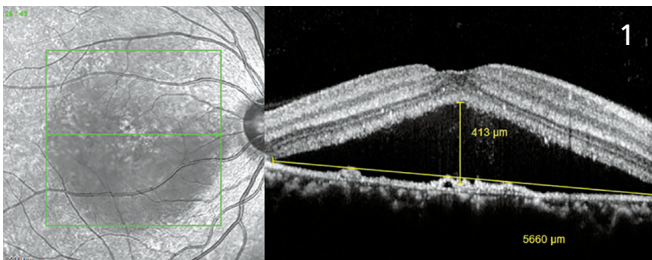


Figure 1. Oct. 27, 2015 | prior to MicroPulse: OD neurosensory detachment 413 μm in height and 5,660 μm in width | CRT 619 μm | VA 20/100; **Figure 2.** Oct. 27, 2015 | prior to MicroPulse: OS neurosensory detachment 219 μm in height and 3,181 μm in width | CRT 286 μm | VA 20/40; **Figure 3.** July 7, 2016 | 9 months post MicroPulse: OD CRT 202 μm and VA 20/20; **Figure 4.** July 7, 2016 | 9 months post MicroPulse OS CRT 198 μm and VA 20/20.

“In addition to being safe and effective, MicroPulse performs efficiently, which is good for both patient and doctor, and at a lower cost than other available treatments.”

associated with CSR. Our patient’s vision was worsening and her anxiety about her reduced vision increased. The condition was fovea-threatening in both eyes; therefore, traditional CW laser was not a good option in terms of safety. Furthermore, because the effects of fluorescein and indocyanine green dye on the fetus aren’t known, we agreed that the risks of angiography to locate the precise location of the choroidal leakage outweighed the benefits. Similarly, because the fetal effects of PDT and anti-VEGF therapy haven’t been adequately studied, we didn’t want to expose the patient and her baby to the potential risks. Instead, we decided to perform bilateral MicroPulse in one session (Table 1).

The IRIDEX IQ 577™ laser was used in MicroPulse mode. MicroPulse delivers energy in packages of short, repetitive pulses that are sufficiently separated from

each other to allow the tissue to cool between pulses. This low-intensity exposure prevents thermal damage to the retina and allows high-density (confluent) delivery for maximum effect.³

SINGLE MICROPULSE TREATMENT STILL EFFECTIVE AT 9 MONTHS

Our patient returned to the clinic for follow-up 1 month after MicroPulse. She felt her vision was greatly improved and declined OCT evaluation. Her BCVA was OD 20/40 and OS 20/20. Four months after MicroPulse, the serous detachments in both eyes were resolved, the macula was fluid-free, and BCVA in each eye was 20/20 (Figures 3 and 4). We last saw our patient in July 2016, 9 months after MicroPulse and 3.5 months post partum, and her visual results have been maintained.

VERSATILITY OF MICROPULSE LASER

In addition to being effective in this special case, where no other treatment would have been appropriate, MicroPulse is a successful treatment in our practice for a number of other retinal conditions. We use it as first-line therapy to treat pseudophakic cystoid macular edema and macular edema due to retinal vein occlusion and diabetes when central retinal thickness (CRT) is less than 400 µm. In cases of retinal vein occlusion and diabetic macular edema in which CRT is 400 µm or more, we find it is most effective to treat with an anti-VEGF agent until the edema decreases to less than 400 µm, and then use MicroPulse.

In addition to being safe and effective, MicroPulse performs efficiently, which is good for both patient and doctor, and at a lower cost than other available treatments. ■

Table 1. TREATMENT PARAMETERS

IQ 577 MicroPulse treatment with TxCell™ Scanning Laser Delivery System for central serous chorioretinopathy

- Wavelength: 577 nm
- Duty cycle: 5%
- Spot size on slit lamp adapter: 100 µm
- Contact lens: Ocular Mainster 2x
- Exposure duration: 200 ms
- Power: 400 mW
- OD: 441 confluent spots applied to lesion and slightly beyond, including the fovea, 7X7 treatment grid.
- OS: 1,471 confluent spots applied to lesion and slightly beyond, including the fovea, 7X7 treatment grid

REFERENCES

1. Liew G, Quin G, Gillies M, Fraser-Bell S. Central serous chorioretinopathy: a review of epidemiology and pathophysiology. *Clin Experiment Ophthalmol.* 2013;41(2):201-214.
2. Dorin G. Subthreshold and micropulse diode laser photocoagulation. *Semin Ophthalmol.* 2003;18(3):147-153.
3. Roisman L, Magalhães FP, Lavinsky D, et al. Micropulse diode laser treatment for chronic central serous chorioretinopathy: a randomized pilot trial. *Ophthalmic Surg Lasers Imaging Retina.* 2013;44(5):465-470.



To learn more about MicroPulse, go to www.iredex.com/micropulse

Treatment techniques and opinions presented in this case report are those of the author. IRIDEX lasers are cleared for retinal photocoagulation of vascular and structural abnormalities of the retina and choroid; and iridotomy, iridectomy and trabeculoplasty in angle-closure glaucoma and open-angle glaucoma. IRIDEX assumes no responsibility for patient treatment and outcome. IRIDEX, IRIDEX logo, and MicroPulse are registered trademarks, and IQ 577 and TxCell are trademarks of IRIDEX Corporation.

IRIDEX | 1212 Terra Bella Avenue | Mountain View, CA 94043 | 800.388.4747 (U.S. inquiries) | info@iredex.com (U.S. & int'l inquiries) | www.iredex.com

© 2016 IRIDEX Corporation. All rights reserved. LT0636