

## ORIGINAL ARTICLE

# MicroPulse™ transscleral cyclophotocoagulation in the treatment of canine glaucoma: Preliminary results (12 dogs)

Lionel Sebbag  | Rachel A Allbaugh | Rachel A Strauss | Travis D Strong |

Rita F Wehrman | Braidee C Foote | Gil Ben-Shlomo 

Department of Veterinary Clinical Sciences, College of Veterinary Medicine, Iowa State University, Ames, Iowa

**Correspondence:** Lionel Sebbag, Department of Veterinary Clinical Sciences, College of Veterinary Medicine, Iowa State University, Ames, IA (lsebbag@iastate.edu).

## Abstract

**Objective:** To describe the clinical application and effect of MicroPulse™ transscleral cyclophotocoagulation (MP-TSCPC) in dogs with glaucoma.

**Animals studied:** Twelve dogs with primary (n = 8) or secondary (n = 4) glaucoma, aged 2-13 years (mean ± SD, 7.2 ± 3.8 years).

**Procedures:** MP-TSCPC was performed under sedation or general anesthesia. Laser duty cycle was 31.3%, laser power varied from 2000-2800 mW, and each hemisphere was treated for 90-180 seconds. The probe was applied to each quadrant in a “sweeping motion,” sparing the 3 and 9 o'clock positions.

**Results:** The number of MP-TSCPC procedures per eye varied from 1 to 3 (1.4 ± 0.7). Intraocular pressure (IOP) was controlled (<25 mm Hg) in 11/12 dogs (92%) within 1-15 days post-operatively. The IOP control at 1 month and the duration between repeated procedures were significantly greater in eyes treated with high energy laser (2800 mW) compared to 2000-2500 mW. Long-term follow-up (315.3 ± 100.7 days) showed controlled IOP in 5/12 (42%) and vision retention in 4/8 (50%) dogs. In unsuccessful cases, loss of IOP control or vision loss occurred within 3-245 days (109.1 ± 93.7 days) and 28-261 days (114 ± 101.6 days), respectively, resulting in a salvage procedure in 6 dogs. Complications were as follows: corneal hypoesthesia (92%), anterior uveitis (67%), post-operative ocular hypertension (50%), neurotrophic corneal ulcer (25%), keratoconjunctivitis sicca (8%), and rubeosis iridis (8%).

**Conclusions:** MP-TSCPC is a viable tool for managing canine glaucoma, although further studies are required to improve the long-term effect and reduce the complication rate.

## KEYWORDS

cyclophotocoagulation, diode laser, dog, glaucoma, intraocular pressure, micropulse

## 1 | INTRODUCTION

Glaucoma, a progressive optic neuropathy associated with increased intraocular pressure (IOP), is a leading cause of ocular discomfort and irreversible blindness in dogs and other species.<sup>1</sup> Medications alone are often insufficient to manage glaucoma long term, requiring surgical intervention

to maintain vision and IOP control. Surgical treatment of glaucoma is directed toward altering aqueous humor production, drainage, or a combination of both.<sup>1</sup> A common surgical treatment for canine glaucoma is transscleral cyclophotocoagulation (TSCPC).<sup>1</sup> Traditional TSCPC uses continuous-wave diode laser to destroy the ciliary body pigmented epithelium, thereby decreasing aqueous

production. Although studies in dogs have shown acceptable IOP control with traditional TSCPC, the resulting visual outcome is often poor given the high incidence of complications such as corneal ulceration, intraocular inflammation, intraocular hemorrhage, cataract formation, retinal detachment, hypotony, and phthisis bulbi.<sup>2-4</sup> Some of these complications may be due to the pronounced tissue disruption and collateral damage from the diode laser procedure.<sup>2</sup>

MicroPulse™ transscleral cyclophotocoagulation (MP-TSCPC) offers a safe and effective alternative to traditional TSCPC in humans.<sup>5-9</sup> With this system, the laser beam is “chopped” into a train of repeated short, microsecond, “on” pulses followed by longer-duration “off” intervals. This pulsatile nature allows the surrounding tissue to cool-off between the pulses, resulting in minimal collateral damage. Aquino and colleagues randomized 48 human patients to receive either MP-TSCPC or traditional TSCPC.<sup>5</sup> At 12 months, 75% of MP-TSCPC and 29% of TSCPC patients achieved an IOP lower than 21 mm Hg. Furthermore, greater vision-threatening complications were noted in the traditional TSCPC group, with higher rates of prolonged inflammation, prolonged hypotony and phthisis bulbi.<sup>5</sup>

The present study describes preliminary results of MP-TSCPC in dogs with glaucoma, detailing the impact of the procedure on various outcomes including intraocular pressure control, vision retention, number of anti-glaucoma medications post-operatively and complication rate.

## 2 | MATERIAL AND METHODS

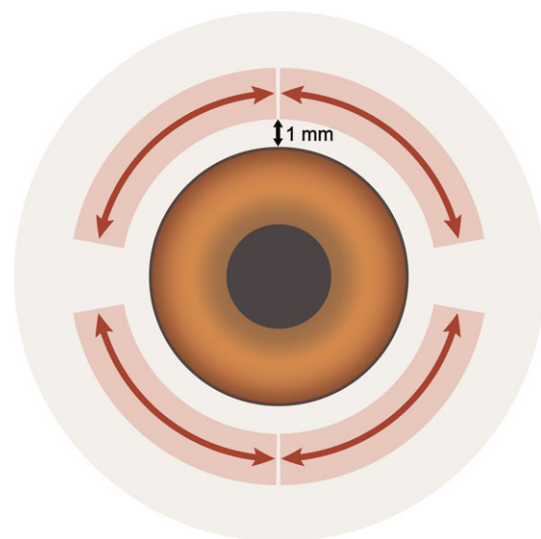
### 2.1 | Animals

Dogs were recruited from client-owned patients diagnosed with uncontrolled glaucoma by an ophthalmology clinician at Iowa State University's Lloyd Veterinary Medical Center based on consistent clinical signs and intraocular pressure (IOP)  $\geq 25$  mm Hg.<sup>1</sup> Patients were excluded if glaucoma developed secondary to intraocular neoplasm. The study was approved by the Institutional Animal Care and Use Committee of Iowa State University (protocol # 9-16-8364-K), and all owners signed a consent form. At enrollment, all patients underwent a complete ophthalmic examination including slit-lamp biomicroscopy, indirect fundoscopy, Schirmer tear test-1 (STT-1), rebound tonometry (TonoVet, Icare Finland Oy, Helsinki, Finland), corneal esthesiometry (Cochet-Bonnet esthesiometer, Luneau Ophtalmologie, Chartres, France), and fluorescein staining of the ocular surface.

### 2.2 | Procedure

Immobilization was performed with either short general anesthesia ( $n = 4$ ) or reversible sedation ( $n = 8$ ). While the

anesthetic protocol varied for each patient (based on the anesthesiologist's preference), sedation was consistently performed with intravenous dexmedetomidine (3-4  $\mu\text{g}/\text{kg}$ ; Dexdomitor®, Zoetis, NJ, USA) and methadone (0.5 mg/kg; Mylan Pharmaceuticals Inc., Rockford, IL, USA). This sedation protocol achieved adequate immobilization and analgesia for the procedure, although one case had to be converted to general anesthesia given the impact of the dog's heavily pigmented bulbar conjunctiva on the laser procedure. Each patient was closely monitored using the guidelines of the American Animal Hospital Association.<sup>10</sup> The affected eye received topical 0.5% proparacaine (Bausch & Lomb, Rochester, NY, USA) followed by 2.5% hypromellose ophthalmic solution (Gonak, Akorn Inc., Somerset, NJ, USA) to lubricate the corneal surface and facilitate probe motion over the bulbar conjunctiva. The laser probe was positioned 1 mm posterior to the limbus, thus targeting the laser beam application 4 mm posterior to the limbus. Each quadrant was treated with a “sweeping motion”, applying laser energy uniformly across the sclera 360° except for the 3 and 9 o'clock positions (Figure 1). The duty cycle was set to 31.3% (ie, 0.5 ms of “on time” and 1.1 ms of “off time”), and the laser energy varied from 2000 to 2800 mW. The treatment duration varied from 45 to 90 seconds per quadrant, ie, 90 to 180 seconds per hemisphere (Table 1). Scleral exposure was facilitated by fixating the perilimbal bulbar conjunctiva with a microalligator clip (1.25”, Gardner Bender, Menomonee Falls, WI) first temporally and then nasally to improve visualization of the temporal and nasal quadrants, respectively (see supplementary video). At completion of the procedure,



**FIGURE 1** Schematic of a canine eye showing the MicroPulse™ probe placement (positioned 1 mm posterior to the corneoscleral limbus) and the “sweeping motion” used to treat each scleral quadrant separately, sparing the 3 o'clock and 9 o'clock positions

sedation was reversed with intramuscular atipamezole (Antisedan®, Zoetis, NJ, USA) or anesthesia was discontinued, and non-diabetic patients received an intravenous injection of dexamethasone (0.15 mg/kg; Dexamethasone-SP, VetOne, Boise, ID, USA). MP-TSCPC was repeated in some cases using similar technique, weeks to months following the initial procedure. In a single case, the repeated MP-TSCPC procedure was combined with a gonioimplant (VS3 Ahmed glaucoma valve, New World Medical, Rancho Cucamonga, CA, USA).

### 2.3 | Post-operative care

Dogs were hospitalized for 24 hours to better assess the short-term impact of the MicroPulse™ laser on the canine eye. During this time, all patients received frequent lubrication (i-Drop Vet Plus q2-4h; I-Med Pharma Inc., Quebec, Canada; or Optixcare q2-4h; Aventix, Ontario, Canada), topical anti-glaucoma medications (typically dorzolamide–timolol q8-12h; Hi-Tech Pharmacal CO., Inc., Amityville, NY, USA; and latanoprost q8-12h; Akorn Inc., Somerset, NJ, USA), and a systemic anti-inflammatory (prednisone 0.5 mg/kg PO q12h; Westward Pharmaceuticals Corp., Eatontown, NJ, USA; or carprofen 2.2 mg/kg PO q12h in diabetic dogs; Rimadyl®, Pfizer Animal Health, New York, NY, USA). Intraocular pressure was assessed at 1 hour and 2 hours post-operatively, then every 2 hours thereafter until the patient was sent home. If post-operative IOP rose above 25 mm Hg within 24 hours following surgery, intravenous mannitol (1–2 g/kg) was administered slowly over 20 minutes and water was subsequently withheld for 4 hours. The owners were instructed to continue the medications described above except for a reduced frequency in lubrication (i-Drop Vet Plus or Optixcare q6-8h) for all and the addition of a neuro-protective medication (memantine, 20 mg PO twice weekly; Dr Reddy's Laboratories, Hyderabad, India) in selected cases (# 10, 11, 12).

Recheck examinations were performed at approximately 1 week, 1 month, 3 months, 6 months, and 12 months post-operatively, with additional visits scheduled in between the aforementioned time points depending on the status of each case and the owner's concerns. At each visit, a complete ophthalmic examination was performed as described above. Anti-glaucoma medications were adjusted as deemed appropriate by the clinician in charge, and topical cyclosporine 1% (compounded in corn-oil) was used if Schirmer tear test-1 was <15 mm/min along with clinical signs consistent with keratoconjunctivitis sicca. If needed as a salvage procedure in blind and painful eyes, a chemical ciliary body ablation (CBA) was performed using an intravitreal injection of either 562.5 µg cidofovir alone (Vistide, Gilead Sciences Inc., Foster City, CA, USA)<sup>11</sup> or 25 mg gentamicin (VetOne, Boise, ID, USA) combined with 1 mg dexamethasone.

### 2.4 | Data analysis

Intraocular pressure was considered “controlled” if the IOP was lower than but not equal to 25 mm Hg, and the eye considered visual if there was a consistent positive menace response, regardless of factors that could impair the quality of vision (eg, keratitis). In each case, time to failure in controlling IOP and time to failure in retaining vision were calculated as the average between the last visit (in days post-operatively) in which IOP was controlled or vision was present, respectively, and the following visit (in days post-operatively) in which IOP was greater than 25 mm Hg or vision was absent in the treated eye, respectively. For comparison of surgical outcomes, the timing of surgical intervention in relation to diagnosis of glaucoma was defined as either “early intervention” (≤2 weeks) or “late intervention” (≥3 weeks). All data are presented as mean ± standard deviation and range (minimum-maximum). The Fisher's exact test was used to investigate the percentage of dogs that had controlled IOP at 1 month (ie, before MP-TSCPC had to be repeated in certain cases), comparing laser energies of 2000–2500 mW vs 2800 mW and comparing “early intervention” vs “late intervention” groups. A student's *t* test was used to compare the duration (in days) between repeated procedures when the initial laser power was set to either 2000–2500 mW or 2800 mW. The same test was used to compare the number of daily anti-glaucoma drops used before MP-TSCPC vs the last follow-up visit post-surgery. Statistical analysis was performed using Sigma-Plot version 13.0 (Systat software Inc., San Jose, CA), and values of *P* < 0.05 were considered statistically significant.

## 3 | RESULTS

MicroPulse™ TSCPC was performed in 14 dogs between October 2016 and March 2017, but one case was lost to follow-up within 10 days of therapy, and one case was secondary to uveal melanoma. Thus, data are reported for 12 dogs and are summarized in Table 1. The mean ± SD age was 7.2 ± 3.8 years (range: 2–13 years). The cause of glaucoma was either primary (n = 8) or secondary (n = 4; 2 post-phacoemulsification, 1 chronic uveitis, 1 lens subluxation), with a duration of 77.6 ± 111.7 days (1–360 days) and a baseline intraocular pressure of 56.8 ± 21.9 mm Hg (28–95 mm Hg) despite aggressive medical treatment. In some cases, the IOP was reduced immediately prior to MP-TSCPC procedure with either intravenous mannitol administration (1–2 g/kg; cases # 7, 8, 9, 12) or aqueocentesis (case # 10). The laser power and duration of therapy are described in Table 1. The mean ± SD (range) number of

**TABLE 1** Details of 13 dogs treated with MP-TSCPC including signalment, etiology and duration of glaucoma prior to MP-TSCPC, pre-operative and post-operative status

Case #	Age (y)	Breed	Sex	Cause of glaucoma	Before procedure <sup>a</sup>				Laser				Last follow-up			
					Glaucoma duration (d)	# Anti-glaucoma drops per day	IOP (mmHg)	Vision	# procedures (days from previous laser)	Laser power (mW)/Duration per hemisphere (s)	POH (Y/N)	Follow-up (d)	Salvage procedure (d)	# Anti-glaucoma drops per day <sup>c</sup>	IOP last visit (IOP before CBA)	Vision
1	5	Blue heeler	FS	Secondary (phacoemulsification, intumescent diabetic cataract)	62	4	29	N	1	2000/90	N	415	CBA (12), cidofovir	4	24 (42)	N
2	12	Australian Shepherd	MN	Primary	90	6	28	Y	1 2 (34)	2000/90 2500/90	Y Y	357	CBA (154), cidofovir	6	16 (59)	N
3	11	French Bulldog X	FS	Secondary (chronic uveitis)	6	3	72	Y	1	2000/180	Y	279	CBA (261), cidofovir	6	5 (38)	N
4	6	Shih Tzu X MN	MN	Primary	21	6	74	Y	1 2 (23) 3 (28)	2000/180 2500/180 2800/180	Y N Y	419	N/A	11	24	Y
5	2	Beagle	FS	Secondary (lens subluxation)	240	6	44	N	1 2 (29)	2000/120 2500/180	Y Y	412	N/A	3	33	Y
6	5	Boston Terrier	FS	Secondary (phacoemulsification, mature cataract)	360	6	75	N	1	2500/120	N	342	CBA (132), gentamicin/ dexameth	6	4 (67)	N
7	3	Beagle X	FS	Primary	90	4	95	Y	1	2800/180	N	160	CBA (91), cidofovir	6	2 (30)	N
8	8	Chow Chow	FS	Primary	42	6	60	N	1	2800/180	Y	362	N/A	6	19	N
9	6.5	Siberian Husky	MN	Primary	10	6	49	Y	1	2800/120	N	90	Enucleation (90)	6	80	N
10	3.5	Siberian Husky	FS	Primary	7	6	35	Y	1	2800/180	Y	304	N/A	2	11	Y
11	13	Shiba Inu	FS	Primary	1	6	75	Y	1 2 (155)	2800/180 2800/180 <sup>b</sup>	N N	335	N/A	1	14	Y
12	7.5	Shiba Inu	FS	Primary	7	6	54	Y	1 2 (189)	2800/180 2800/180	N N	308	N/A	8	17	Y

CBA, Ciliary body ablation; N/A, Not applicable; POH, Post-operative ocular hypertension.

<sup>a</sup>Baseline data reported for the last procedure in cases that had repeated MP-TSCPC.<sup>b</sup>MP-TSCPC was combined with Ahmed gonioplasty in this repeated procedure.<sup>c</sup>Immediately prior to salvage procedure (when applicable) or at the last follow-up visit.

**TABLE 2** Follow-up information in 12 dogs treated with MP-TSCPC, detailing the mean  $\pm$  standard deviation IOP in the subset of dogs that retained IOP control ( $<25$  mm Hg) at each visit, and the time to failure (d) in dogs that lost IOP control between follow-up visits

	1 mo	3 mo	6 mo	Last visit
% dogs with IOP $< 25$ mm Hg	83% (10/12)	83% (10/12)	50% (6/12)	42% (5/12)
IOP in controlled cases (mm Hg)	$16.5 \pm 7.7$	$16.7 \pm 6.4$	$20.5 \pm 4.8$	$17.0 \pm 4.9$
Time to failure in uncontrolled cases (d)	$11.5 \pm 12.0$	N/A	$93.7 \pm 39.5$	245

N/A, not applicable.

laser procedures per eye was  $1.4 \pm 0.7$  (range: 1-3). Most eyes were only treated once ( $n = 7$ ), while some eyes were treated twice ( $n = 4$ ) and 1 eye was treated three times. The mean  $\pm$  SD (range) duration between repeated procedures was statistically greater ( $P < 0.001$ ) when the initial procedure power was 2800 mW ( $172 \pm 24$  days; range 155-189 days) compared to either 2000 or 2500 mW ( $28.3 \pm 5.5$  days; range 23-34 days). A very subtle “pop” sound was noted in 6/12 dogs (50%), ranging from 1-2 soft “pops” per hemisphere. The duration of MP-TSCPC procedure in each eye was between 5 and 10 minutes. Follow-up time ranged from 90-419 days, with mean  $\pm$  SD of  $315.3 \pm 100.7$  days. During that time, the number of anti-glaucoma drops used per day in each dog decreased from  $5.6 \pm 0.8$  drops (3-6 drops) when uncontrolled at baseline, to  $5.4 \pm 2.7$  drops (1-11 drops) at the last follow-up visit, although the difference was not statistically significant ( $P = 1.000$ ).

### 3.1 | IOP control

When considering the first procedure performed in each dog, the percentage of dogs with IOP  $< 25$  mm Hg at 1 month post-operatively was 17% with either 2000 or 2500 mW (1/6 dogs) and 100% with 2800 mW (6/6 dogs). The difference

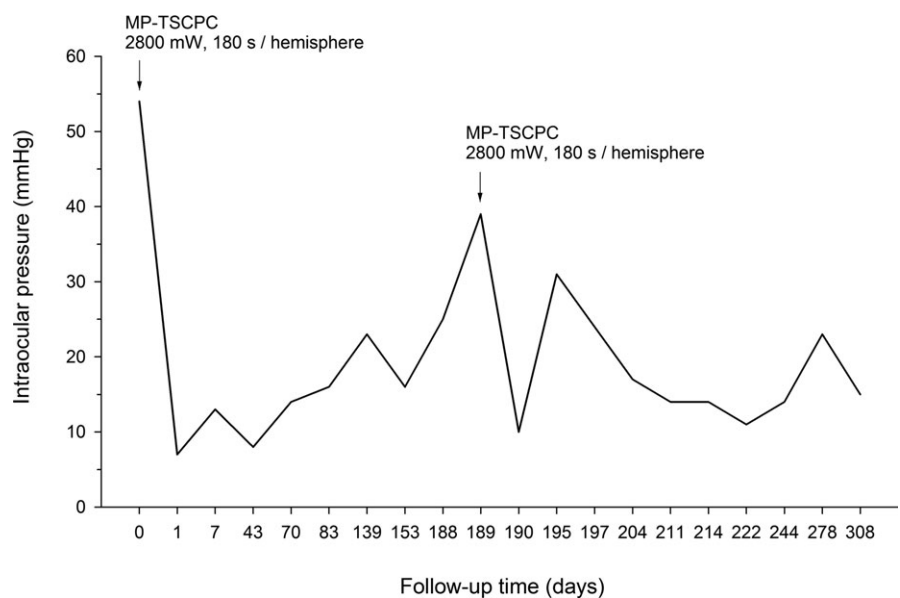
between 2000-2500 mW and 2800 mW was significant ( $P = 0.015$ ). Given the poor results of the low energy levels, the following efficacy data depicts IOPs obtained after repeated procedures with higher energy levels.

IOP decreased below 25 mm Hg in 11/12 dogs (92%) within  $6.5 \pm 5.9$  days (1-15 days). IOP control at 1 month post-operatively (83%, 10/12 dogs) was noted in 100% (5/5 dogs) and 71% (5/7 dogs) of patients with “early intervention” or “late intervention,” respectively. This difference was not statistically significant ( $P = 0.205$ ). At the last follow-up visit, 5/12 (42%) had controlled IOP with a mean IOP of  $17.0 \pm 4.9$  mm Hg (Table 2), while IOP control was lost in the other 7 cases within  $109.1 \pm 93.7$  days (3-245 days). Figure 2 depicts an IOP curve over time in a representative dog (case #12) that received two MP-TSCPC treatments with 2800 mW for 180 seconds per hemisphere, with the second procedure 189 days after the first.

### 3.2 | Vision status

Out of 4 dogs that were blind before MP-TSCPC, 3/4 remained non-visual post-operatively, while one case (patient #5) regained vision and remained sighted at the last visit (Day 412). Of dogs that were visual before laser

**FIGURE 2** Representative intraocular pressure curve over time in a 7.5-y-old female spayed Shiba Inu dog diagnosed with primary glaucoma (case #12). Baseline IOP (54 mm Hg) decreased to 7 mm Hg within 1 d of the initial MP-TSCPC procedure and then remained below 25 mm Hg for over 6 mo. MP-TSCPC was repeated on day 189 post-operatively as IOP spiked to 39 mm Hg. The second MicroPulse™ procedure controlled IOP within 8 d (day 197) and maintained IOP below 25 mm Hg until the last follow-up visit (day 308)





therapy, 4/8 dogs remained sighted throughout the duration of the study, while 4/8 lost vision within  $114 \pm 101.6$  days (28-261 days).

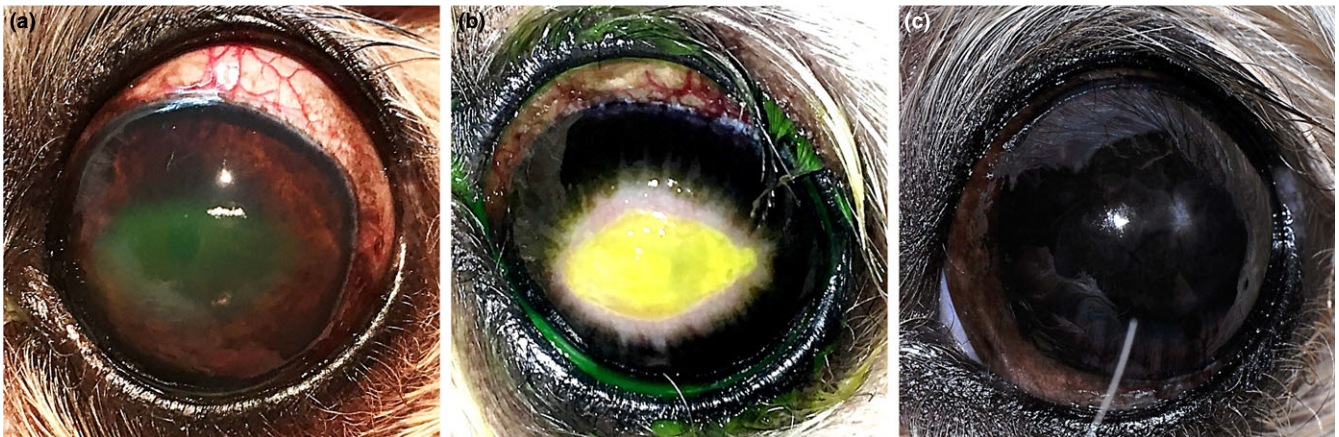### 3.3 | Salvage procedures

A CBA was performed in 5 dogs at  $130 \pm 91.1$  days (12-261 days) following MP-TSCPC. The procedure was successful in controlling IOP in all cases, although CBA had to be repeated once in one dog. Enucleation was performed in 1 dog (case #9) at 90 days post-MP-TSCPC. Histopathological evaluation performed at Iowa State University revealed goniodysgenesis, pre-iridal fibrovascular membrane, subtle scleral hyalinization yet no noticeable damage to the ciliary body.

### 3.4 | Complications

All cases developed conjunctival hyperemia post-operatively, a finding that was accounted for as an “expected adverse effect” and not a complication. Conjunctival hyperemia was mild to moderate and resolved within 1-2 weeks following surgery. Of note, not a single dog developed hyphema, cataract or retinal separation. By decreasing order of frequency, the complications of MP-TSCPC were:

1. Corneal hypoesthesia (n = 11, 92%): Central corneal touch threshold was  $2.5 \pm 1.0$  cm (0.5-4.5 cm) at baseline and decreased to  $1.3 \pm 0.9$  cm (0-3 cm) at 1 week following MP-TSCPC.
2. Anterior uveitis (n = 8, 67%): Mild and transient anterior uveitis (trace to 1+ flare) was noted in cases for which laser power was set to 2500 or 2800 mW. In most cases, the inflammation resolved within 1-2 weeks.
3. Post-operative ocular hypertension (n = 6, 50%): POH occurred in 6 dogs and in 9/18 laser procedures (50%), with a mean  $\pm$  SD (range) time from laser therapy of  $1.8 \pm 1.0$  hours (1-4 hours) and an IOP of  $40.7 \pm 12.7$  mmHg (27-69 mmHg).
4. Neurotrophic corneal ulcer (n = 3, 25%): A superficial corneal ulcer developed post-operatively in 3 cases within the first few weeks post-operatively (day 5 in case #3, day 3 in case #4 and day 20 in case #5). All affected dogs were brachycephalic breeds, and the ulcer was characterized by an axial location with loose epithelial edges (Figure 3A) and concurrent corneal hypoesthesia (corneal touch threshold = 1.0 cm in all 3 dogs). Despite aggressive therapy with topical antimicrobials, heterologous serum, and temporary tarsorrhaphy (2/3 cases), the neurotrophic corneal ulcers were slow to heal, taking 53 days in case #3, 120 days in case #4, and 16 days in case #5. In case #4, the healing process involved dense granulation tissue and perilesional corneal melanosis (Fig. 3B), resulting in chronic pigmentary changes (Figure 3C).
5. Keratoconjunctivitis sicca (n = 1, 8%): In one dog (case #12), the Schirmer tear test-1 value decreased from 15 mm/min at baseline to 4 mm/min 43 days following MP-TSCPC, which coincided with a reduction in central corneal touch threshold (4.5 cm at baseline, 3.5 cm at 43 days). Therapy with twice-daily cyclosporine 1% rapidly improved Schirmer values in the affected eye (22 mm/min at last visit).
6. Conjunctival burn (n = 1, 8%): A linear conjunctival burn occurred underneath the path of the laser probe in one dog that had heavily pigmented bulbar conjunctiva (case #10). In that case, the sedation was converted to general anesthesia so that a conjunctival incision could be performed to access the scleral tissue with the MicroPulse™ probe.



**FIGURE 3** A neurotrophic corneal ulcer developed in case #4 three days following the second MP-TSCPC procedure (A). Dense granulation tissue and perilesional corneal melanosis developed over the next few weeks (B, day 59). The ulcer healed by day 120 but dense melanosis remained in the axial cornea long term (C, day 215)

7. Rubeosis iridis (n = 1, 8%): Multiple fine iridal blood vessels were noted in case #9 at 60 days post-operatively. Twenty-nine days later (day 89), IOP spiked to 80 mm Hg and, following enucleation, histopathological evaluation demonstrated the presence of a pre-iridal fibrovascular membrane.

## 4 | DISCUSSION

The majority of dogs treated with MP-TSCPC (11/12, 92%) initially responded favorably to the procedure and maintained IOP <25 mm Hg for 3 months (10/12, 83%), similar to findings by Sapienza and colleagues, who reported IOP control in 81.2% of treated canine eyes at 2 months post-operatively.<sup>12</sup> Long-term follow-up of our dogs (mean 315 days) showed IOP control and retention of vision in 42% and 50% of cases, respectively. A similar trend was reported in human patients, for whom IOP control was present in 89.5% of cases at 2 months,<sup>7</sup> 75% at 12 months and 52% at 18 months post-operatively.<sup>5</sup> Of note, our findings likely underestimated the potential success rate of MP-TSCPC as the laser energy used in the first few dogs was suboptimal (ie, less than 2800 mW). The laser energy was initially set to that described in human patients (2000 mW).<sup>5,6</sup> Based on response to therapy (or lack thereof), the power was gradually increased from 2000 mW to 2500 mW to 2800 mW. Furthermore, the duration of therapy was gradually increased from 90 seconds to 180 seconds per hemisphere, consistent with a protocol used in a more recent study in human patients.<sup>9</sup>

MicroPulse™ TSCPC may be complimentary to other surgical therapies of glaucoma as the presumed mechanism of action of this procedure is different. Whereas continuous-wave TSCPC is decreasing aqueous humor production by destroying the ciliary body epithelium,<sup>1</sup> MP-TSCPC may increase aqueous humor drainage by changing the position of the trabecular meshwork and scleral spur (as shown in an ex vivo model of primate eyes),<sup>13</sup> somewhat similar to the chronic use of topical pilocarpine, although this claim requires verification in future canine studies. Further, MicroPulse™ has several advantages and drawbacks compared to other surgical modalities. The strengths of MP-TSCPC include (a) *Rapidity of the procedure*: The entire procedure was generally completed in less than 10 minutes, especially if performed under reversible sedation. In fact, sedation combined with an opioid was the preferred immobilization method of the authors as sedation provided adequate analgesia and the scleral exposure was not negatively affected by anesthesia-induced ventral strabismus; (b) *Rapidity of IOP reduction*: IOP decreased below 25 mm Hg within 24 hours in 5 dogs—consistent with findings in human patients<sup>5,6</sup>—and within 6.5 days

on average for 11/12 dogs that responded favorably to MP-TSCPC in the short term. This rapid IOP-lowering effect may be due to enhanced uveoscleral and/or conventional outflow of aqueous humor;<sup>6,13</sup> (c) *Minimal inflammation*: The amount of post-operative intraocular inflammation was minimal to non-existent. When present (67% cases), the Tyndall effect was graded as trace or 1+ aqueous flare and, similar to reports in humans,<sup>6,9</sup> resolved within the first 2 weeks post-operatively. The minimal inflammation induced by the MicroPulse™ technology is particularly attractive when considering a combination procedure of TSCPC with an anterior chamber shunt (such as Ahmed gonioimplant). This combination surgery was completed in a single dog (case # 11) when IOP gradually increased ~5.5 months after the initial MP-TSCPC, and that dog has remained visual with controlled IOP at the last visit (ie, 6 months following combination surgery). Further, none of the dogs in the present study developed cataract, unlike patients that were treated with Nd:YAG TSCPC<sup>14</sup> or continuous-wave diode laser TSCPC;<sup>3,4</sup> (d) *Effective in subalbinotic eyes*: Unlike Nd:YAG laser,<sup>14</sup> MP-TSCPC was successfully performed in two Siberian Husky dogs that had subalbinotic eyes, one of which maintained vision and controlled IOP at the last follow-up visit (304 days).

The main drawback of MP-TSCPC is the relative short-term effect of the procedure on the eye. The need to repeat MP-TSCPC is well documented in the human literature,<sup>5-9</sup> and was also noted in the present canine study. Despite an excellent response of dogs #11 and #12 to the initial MP-TSCPC procedure, IOP spiked again after 5-6 months, and a repeated MP-TSCPC was performed at 155-189 days post-operatively. The timing for repeating MP-TSCPC is likely influenced by each individual situation and warrants further investigation. Another disadvantage of MP-TSCPC is the impact of the procedure on corneal sensitivity, a complication noted at a very high frequency (11/12, 92%). The damage to the long ciliary nerves may be more extensive with MP-TSCPC compared to continuous-wave TSCPC, as the former uses a “sweeping motion” to apply the laser energy uniformly across the sclera 360° (except for the 3 and 9 o'clock positions), while the latter only treats selected areas of the sclera. To reduce the risk of neurotrophic corneal ulceration, one could consider performing a temporary tarsorrhaphy at the completion of MP-TSCPC<sup>4</sup> and/or using peri-operative topical cyclosporine, as this drug has been shown to improve corneo-conjunctival sensitivity.<sup>15</sup> Lastly, the lack of significant reduction in post-operative anti-glaucoma medications represents another disadvantage of MP-TSCPC, and the variability in the number of anti-glaucoma medications used post-operatively could represent another confounding factor in the procedure's efficacy reported herein. The frequency of anti-glaucoma therapy may decrease in the short term,<sup>12</sup> but

eventually returned to near baseline. However, this finding is contrary to studies in human patients and warrants verification by future canine studies that employ standardized MP-TSCPC protocols.<sup>5,6</sup>

The present study is limited by a small sample size and relatively short follow-up time. These limitations restricted our ability to assess the longevity of treatment effect (beyond 12-14 months) or the occurrence of late complications. Further, the potential benefit of memantine for neuroprotection and preservation of vision could not be asserted in the present study due to low numbers (3/12 dogs), variable confounding factors (eg, duration of glaucoma and laser parameters) and uncertainty about the efficacy of the dosage used. The latter was selected empirically based on authors' experience, although future studies are needed to assess safety and efficacy of this drug in canine glaucoma. Nevertheless, our preliminary findings demonstrated that MicroPulse™ is a viable alternative or adjunct to other therapies for managing canine glaucoma. The procedure may work best when using high laser parameters (2800 mW, 180 seconds per hemisphere), and the long-term outcomes may be improved with early intervention for uncontrolled glaucoma.

## ACKNOWLEDGMENTS

The authors thank Jordan Gongora for assistance with image preparation as well as Chimene Peterson and Chelsey Carroll for providing technical support.

## ORCID

Lionel Sebbag  <http://orcid.org/0000-0002-0103-0127>

Gil Ben-Shlomo  <http://orcid.org/0000-0002-7656-3235>

## REFERENCES

1. Maggio F. Glaucomas. *Top Companion Anim Med.* 2015;30:86-96.
2. Nadelstein B, Wilcock B, Cook C, et al. Clinical and histopathologic effects of diode laser transscleral cyclophotocoagulation in the normal canine eye. *Vet Comp Ophthalmol.* 1997;7:155-162.
3. Cook C, Davidson M, Brinkmann M, et al. Diode laser transscleral cyclophotocoagulation for the treatment of glaucoma in dogs: results of six and twelve month follow-up. *Vet Comp Ophthalmol.* 1997;7:148-154.
4. Hardman C, Stanley RG. Diode laser transscleral cyclophotocoagulation for the treatment of primary glaucoma in 18 dogs: a retrospective study. *Vet Ophthalmol.* 2001;4:209-215.

5. Aquino MC, Barton K, Tan AM, et al. Micropulse versus continuous wave transscleral diode cyclophotocoagulation in refractory glaucoma: a randomized exploratory study. *Clin Exp Ophthalmol.* 2015;43:40-46.
6. Tan AM, Chockalingam M, Aquino MC, et al. Micropulse transscleral diode laser cyclophotocoagulation in the treatment of refractory glaucoma. *Clin Exp Ophthalmol.* 2010;38:266-272.
7. Kuchar S, Moster MR, Reamer CB, et al. Treatment outcomes of micropulse transscleral cyclophotocoagulation in advanced glaucoma. *Lasers Med Sci.* 2016;31:393-396.
8. Emanuel ME, Grover DS, Fellman RL, et al. Micropulse cyclophotocoagulation: initial results in refractory glaucoma. *J Glaucoma.* 2017;26:726-729.
9. Lee JH, Shi Y, Amoozgar B, et al. Outcome of micropulse laser transscleral cyclophotocoagulation on pediatric versus adult glaucoma patients. *J Glaucoma.* 2017;26:936-939.
10. Bednarski R, Grimm K, Harvey R, et al. AAHA anesthesia guidelines for dogs and cats. *J Am Anim Hosp Assoc.* 2011;47:377-385.
11. Low MC, Landis ML, Peiffer RL. Intravitreal cidofovir injection for the management of chronic glaucoma in dogs. *Vet Ophthalmol.* 2014;17:201-206.
12. Sapienza J, Kim K, Rodriguez E Short term findings in 25 dogs treated with micropulse transscleral diode cyclophotocoagulation for refractory glaucoma (abstract). 48th Annual Conference of the American College of Veterinary Ophthalmologists 2017; 20:E1-E19.
13. Johnstone M, Padilla S, Wen K, et al. Transcleral laser induces aqueous outflow pathway motion and reorganization (abstract). 27th Annual Meeting of the American Glaucoma Society Annual Meeting 2017.
14. Nasisse MP, Davidson MG, English RV, Jamieson V, Harling DE, Tate LP. Treatment of glaucoma by use of transscleral neodymium:Yttrium aluminum garnet laser cyclocoagulation in dogs. *J Am Vet Med Assoc.* 1990;197:350-354.
15. Toker E, Asfuroglu E. Corneal and conjunctival sensitivity in patients with dry eye: the effect of topical cyclosporine therapy. *Cornea.* 2010;29:133-140.

## SUPPORTING INFORMATION

Additional Supporting Information may be found online in the supporting information tab for this article.

**How to cite this article:** Sebbag L, Allbaugh RA, Strauss RA, et al. MicroPulse™ transscleral cyclophotocoagulation in the treatment of canine glaucoma: Preliminary results (12 dogs). *Vet Ophthalmol.* 2018;00:1–8. <https://doi.org/10.1111/vop.12603>