

Micropulse Laser Therapy for the Treatment of Radiation Retinopathy

This option fills a gap where there is no current standard of care.

BY TIMOTHY G. MURRAY, MD, MBA, FACS

Most choroidal melanomas are currently treated with plaque brachytherapy. Side effects of this treatment can include long-term damage to retinal vascular endothelial cells and capillary closure, the primary vascular event in radiation retinopathy.¹ Studies show that more than 50% of eyes undergoing plaque radiotherapy manifest this pathology by 9 months after treatment,^{2,3} but my experience has been that nearly 100% of patients experience radiation retinopathy at some point after plaque brachytherapy.

There is no standard of care for radiation retinopathy. Intravitreal bevacizumab (Avastin, Genentech), intravitreal triamcinolone acetonide, and laser photocoagulation have

all been studied for the management of radiation retinopathy, but their benefits are transient in nature, and improvements in visual acuity have been limited.⁴ Recent studies have suggested a benefit with early recognition and targeted use of intravitreal anti-VEGF agents,⁵ but there is still room for improvement. For severe radiation retinopathy, we are currently using combination therapy with an intravitreal anti-VEGF agent and intravitreal triamcinolone acetonide.

In an effort to expand the treatment options for radiation retinopathy, I have been evaluating micropulse laser therapy (MPLT) in conjunction with anti-VEGF therapy for patients with radiation retinopathy. MPLT has been

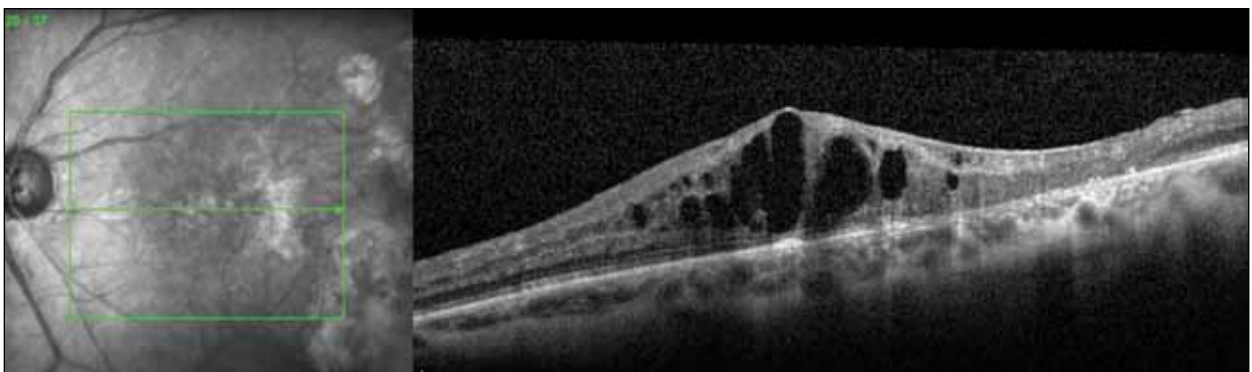


Figure 1. SD-OCT shows severe intraretinal cystic edema. Visual acuity is 20/100.

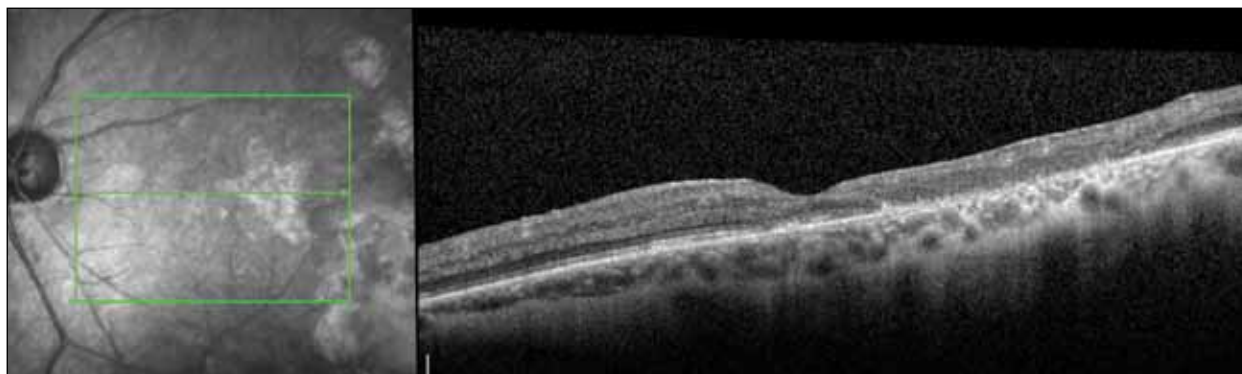


Figure 2. SD-OCT shows that foveal contour is restored. Visual acuity after MPLT is 20/25.

MPLT may be a viable option for treatment in a condition for which there is currently no standard of care.

used effectively in glaucoma and retinal vascular diseases without the typical thermal damage to cells associated with laser treatments.⁶⁻⁸ My initial goal was to use MPLT as an adjunct to reduce the number of intravitreal injections typically required, but my experience has been so positive I am considering using it as a first-line option.

CASE STUDY

A woman, 50 years of age, was treated for posterior uveal melanoma with COMS-configured 125-iodine plaque radiotherapy in March 2009. In July 2012, spectral-domain optical coherence tomography (SD-OCT) revealed severe intraretinal cystic edema (Figure 1), and her visual acuity had decreased to 20/100. Although radiotherapy had produced excellent results with the melanoma, she was now diagnosed with grade 5 radiation retinopathy.

The patient received 3 intravitreal injections of bevacizumab over 6 months. Unfortunately, the patient showed persistent visually compromising radiation maculopathy. We discussed the alternatives, and, after obtaining informed consent, I treated her with MPLT.

I used the IQ 532-nm laser (Iridex) in continuous-wave emission mode using a 100 μ m spot size and 100 ms duration to create a threshold burn. I made the test burn in a location that was away from any visually significant structures, but in a location with comparable pigmentation and thickness to my designated treatment area. I achieved a moderate level of whitening in this patient using 80 mW of

power. I then switched the laser to micropulse emission mode with a 5% duty cycle, 160 mW power (doubled from the power used in the test burn), 100 μ m spot size, and 200 ms pulse duration. I applied 244 micropulses in repetitive pulse mode. I identified the tumor margin and applied the pulses from the margin sectorially toward the foveal avascular zone.

Three months after MPLT, the foveal contour had been restored and the cystic edema resolved, as shown on SD-OCT (Figure 2). Visual acuity improved from 20/100 to 20/25, and no retreatment was required.

CONCLUSION

MPLT may be a viable option for treatment in a condition for which there is currently no standard of care. I look forward to further studies evaluating its long-term efficacy and anticipate using MPLT as a first-line therapy in the future. ■

Timothy G. Murray, MD, MBA, FACS, is the founder of Murray Ocular Oncology and Retina in Miami, FL. He can be reached at tel: +1 305 487 7470; fax: +1 786 567 4380; or email: tmurray@murraymd.com.



1. Archer DB, Amoaku WM, Gardiner TA. Radiation retinopathy—clinical, histopathological, ultrastructural and experimental correlations. *Eye (Lond)*. 1991;5 (Pt 2):239-251.
2. Melia BM, Abramson DH, Albert DM, et al. Collaborative ocular melanoma study (COMS) randomized trial of I-125 brachytherapy for medium choroidal melanoma. I. Visual acuity after 3 years COMS report No. 16. *Ophthalmology*. 2001;108(2):348-366.
3. Diener-West M, Earle JD, Fine SL, et al. The COMS randomized trial of iodine 125 brachytherapy for choroidal melanoma, III: initial mortality findings. COMS Report No. 18. *Arch Ophthalmol*. 2001;119(7):969-982.
4. Wen JC, McCannel TA. Treatment of radiation retinopathy following plaque brachytherapy for choroidal melanoma. *Curr Opin Ophthalmol*. 2009;20(3):200-204.
5. Shah NV, Houston SK, Markoe AM, Feuer W, Murray TG. Early SD-OCT diagnosis followed by prompt treatment of radiation maculopathy using intravitreal bevacizumab maintains functional visual acuity. *Clin Ophthalmol*. 2012;6(1):1739-1748.
6. Fea AM, Bosone A, Rolle T, Brogliatti B, Grignolo FM. Micropulse diode laser trabeculoplasty (MDLT): a phase II clinical study with 12 months follow-up. *Clin Ophthalmol*. 2008;2(2):247-252.
7. Vujosevic S, Bottega E, Casciano M, Pilotto E, Convento E, Midena E. Microperimetry and fundus autofluorescence in diabetic macular edema: subthreshold micropulse diode laser versus modified early treatment diabetic retinopathy study laser photocoagulation. *Retina*. 2010;30(6):908-916.
8. Parodi MB, Spasse S, Iacono P, Di Stefano G, Canziani T, Ravalico G. Subthreshold grid laser treatment of macular edema secondary to branch retinal vein occlusion with micropulse infrared (810 nanometer) diode laser. *Ophthalmology*. 2006;113(12):2237-2242.