

Advances in Cyclophotocoagulation

The evolution of laser glaucoma surgery in the 21st century.

BY JEFFREY A. KAMMER, MD

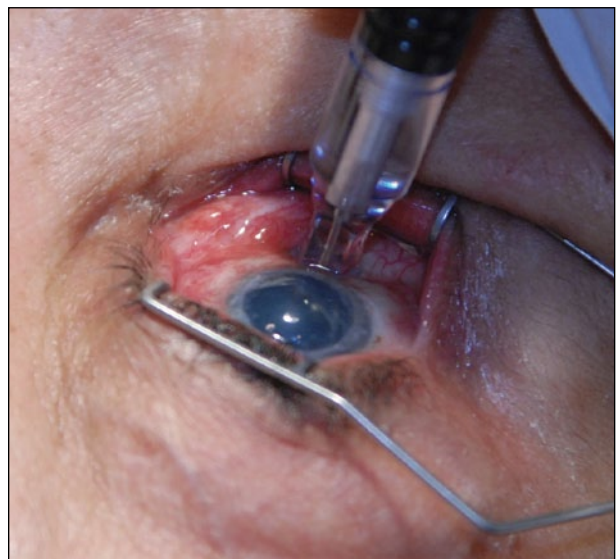
Cyclodestruction has been used to lower IOP in humans since the mid-1930s.¹ Although its IOP-lowering efficacy is excellent, concerns regarding its side effects (eg, vision loss, cystoid macular edema, phthisis, hypotony) led surgeons to reserve transscleral cyclophotocoagulation (CPC) for patients with poor vision and end-stage glaucoma. Emerging data, however, are changing ophthalmologists' perceptions of transscleral CPC and where it fits in the therapeutic paradigm. Technology in development will further redefine this procedure.

DIODE LASER TRANSSCLERAL CPC

New Perspectives

Historically, CPC has been a treatment of last resort when all other modalities have failed. This thought process is based on outdated technology (ie, cyclocryotherapy) and studies of patients with end-stage glaucoma.² In the 21st century, diode CPC is the preferred method of cilioablative therapy owing to its ergonomics, cost, and efficiency (Figure 1). Compared with previous cyclodestructive procedures, diode CPC is much more localized and causes less damage to collateral tissue.

To better appreciate how diode CPC compares to conventional glaucoma surgeries, ophthalmologists must consider two recent reports on the safety and efficacy of diode CPC, tube shunts, and trabeculectomy after 5 years of follow-up. Rotchford et al published the results of a study that evaluated the effects of diode CPC in patients with good ($\geq 20/60$) visual acuity. The investigators found that 73.5% of patients had a final IOP of 16 mm Hg or less and that only 30.6% lost 2 or more Snellen lines.³ In the Tube Versus Trabeculectomy (TVT) study, 63.9% of patients in the tube shunt group and 63.5% of patients in the trabeculectomy group had an IOP of 14 mm Hg or less. Forty-six percent of the tube shunt patients and 43% of the trabeculectomy patients lost 2 or more lines of Snellen visual acuity.⁴



(Courtesy of Rocky Mann, Vanderbilt Eye Institute.)

Figure 1. Diode CPC performed using a G-probe.

These data highlight the comparable efficacy and rate of vision loss among glaucoma patients treated with diode CPC, trabeculectomy, and tube shunts.

Based in part on these promising results, several investigators have evaluated the possibility of using diode CPC as a primary surgical treatment. Egbert and associates prospectively compared primary diode CPC to medical treatment in patients with primary open-angle glaucoma. In the study, the IOP-lowering efficacy was superior in the laser versus the medical group. Specifically, 47% of the diode CPC patients experienced a drop in IOP of 20% or more, and 48% of the patients had a final IOP of 22 mm Hg or less. Both groups experienced a 23% rate of visual decline, but there were no reports of hypotony, phthisis bulbi, or sympathetic ophthalmia in either group.⁵

Similarly, Lai et al studied the use of diode CPC as a primary surgical treatment in patients with medically

(Courtesy of EyeTectCare.)

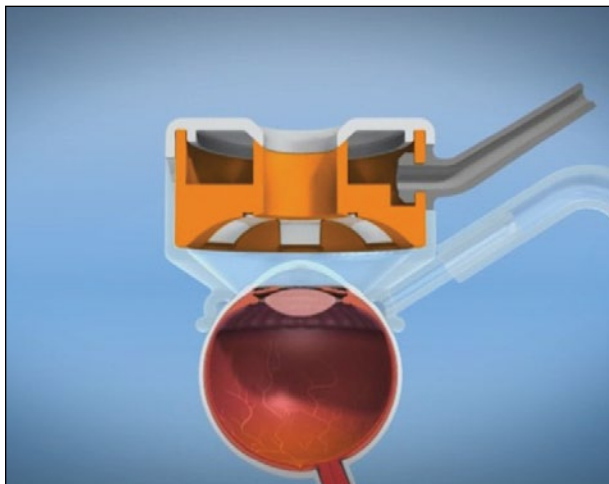


Figure 2. An artistic rendering of the EyeOP1, which uses high-intensity focused ultrasound to perform ciliary body thermocoagulation.

uncontrolled, chronic angle-closure glaucoma. The investigators reported that 92% of the patients had a final IOP of 21 mm Hg or less, with or without adjunctive medication. Although 38.5% experienced a decrease in vision, there were no major complications.⁶

These results clearly demonstrate that, when used as a primary surgical procedure for patients with primary open-angle and chronic angle-closure glaucoma, diode CPC can provide solid IOP lowering with a side effect profile that is similar to that of conventional glaucoma surgeries.

Modifications

Endoscopic Cyclophotocoagulation

Although the aforementioned promising results have not yet prompted a large-scale shift to early diode CPC in glaucoma patients with ambulatory vision, it has emboldened many surgeons to incorporate endoscopic cyclophotocoagulation (ECP) as an adjunct to cataract surgery in patients with ocular hypertension and glaucoma. ECP is a cilioablative procedure that allows direct photocoagulation of the ciliary processes with endoscopic assistance. The specific indications are still in evolution, but the most common use of ECP is in combination with phacoemulsification for the treatment of patients with early to moderate glaucoma. Other documented indications for ECP include (1) the treatment of plateau iris syndrome, (2) the management of patients with refractory glaucoma, (3) the augmentation of the effects of a glaucoma drainage implant, and (4) the treatment of patients who are not good candidates for filtration surgery.

“A recent iteration of transscleral diode laser CPC uses micropulse technology to denature the target tissue while further minimizing collateral tissue damage.”

Slow Coagulation Technique

The most commonly used treatment parameters for diode CPC start at 1,750 to 2,000 mW for 2,000 milliseconds. Typically, surgeons increase the power until they hear a “pop,” at which point they maintain the power or drop it to a level just below when they hear the noise. In reality, this pop represents uveal microexplosions, which can cause significant pain and inflammation. Douglas Gaasterland, MD, proposed a new protocol that employs lower power (1,250-1,500 mW) and a longer duration (3,500-4,500 milliseconds) to provide equal or greater energy in a more comfortable, less destructive manner.⁷ Although published results are pending, the anecdotal reports are promising.

NEW TECHNOLOGY

Micropulse Transscleral Diode Laser CPC

A recent iteration of transscleral diode laser CPC uses micropulse technology to denature the target tissue while further minimizing collateral tissue damage. The device applies a series of short (microsecond), repetitive bursts of energy that effectively confines the thermal effect to the absorbing tissue. In 2010, Tan and associates published the results of a prospective interventional case series. The investigators evaluated 40 eyes with refractory glaucoma that were treated with micropulse transscleral diode CPC using a modified trans-pars plana contact probe (2,000 mW of diode laser energy delivered over 100 seconds with 0.5 milliseconds “on”/1.1 milliseconds “off” and a 31.1% duty cycle). In this study, the mean IOP decreased from 40.1 to 24.6 mm Hg, with no reports of hypotony or postoperative vision loss.⁸

Ultrasound-Mediated Cyclomodification

Ultrasonic cyclocoagulation has been studied since the 1980s, but it has only recently become clinically practical. Unlike a diode laser, ultrasonic energy can be focused

through nonoptically transparent media to produce controlled thermocoagulation without deleterious effects to the surrounding tissue. Moreover, its effects are pigment independent and can be delivered precisely to a defined region within the eye. This technology has become known as *high-intensity focused ultrasound* (HIFU).

A strategy to use HIFU in an efficient, one-step technique is called *ultrasound circular cyclocoagulation*. The first commercially available HIFU unit that incorporates this protocol is known as EyeOP1 (EyeTechCare; Figure 2). The pilot study for this unit was completed in 2011, and it documented a decrease in IOP from 40.5 to 23.4 mm Hg in patients with refractory glaucoma who were treated with an exposure time of 4 seconds.⁹ More recently, a prospective multicenter clinical trial followed 39 eyes with refractory glaucoma that were treated with ultrasound circular cyclocoagulation for 4 seconds. This study documented a decrease in IOP from a baseline value of 28.9 to 18.1 mm Hg.¹⁰ No major complications were reported in either study.

CONCLUSION

During its 85-year existence, CPC has evolved from a last-ditch glaucoma procedure fraught with complications to a refined technique that can be used to manage many different stages of glaucoma. As technology continues to advance, it is likely that CPC's risk-benefit ratio will improve further with a corresponding increase in its acceptance by physicians. ■

Jeffrey A. Kammer, MD, is an associate professor of ophthalmology and the director of the Clinical Trials Unit at Vanderbilt Eye Institute in Nashville, Tennessee. He is a consultant to Iridex. Dr. Kammer may be reached at (615) 936-7190; jeff.kammer@vanderbilt.edu.



1. Weve H. Die zyklodiatermie das corpus ciliare bei glaukom. *Zentralbl Ophthalmol.* 1933;29:562-569.
2. Benson MT, Nelson ME. Cyclocryotherapy: a review of cases over a 10-year period. *Br J Ophthalmol.* 1990;74:103-105.
3. Rotchford AP, Jayasawal R, Madhusudhan S, et al. Transscleral diode laser cycloablation in patients with good vision. *Br J Ophthalmol.* 2010;94:1180-1183.
4. Gedde SJ, Schiffman JC, Feuer WJ, et al. Treatment outcomes in the Tube Versus Trabeculectomy (TVT) study after five years of follow-up. *Am J Ophthalmol.* 2012;153:789-803.
5. Egbert PR, Fiadoyor S, Budenz DL, et al. Diode laser transscleral cyclophotocoagulation as a primary surgical treatment for primary open-angle glaucoma. *Arch Ophthalmol.* 2001;119:345-350.
6. Lai JS, Tham CC, Chan JC, Lam DS. Diode laser transscleral cyclophotocoagulation as primary surgical treatment for medically uncontrolled chronic angle closure glaucoma: long-term clinical outcomes. *J Glaucoma.* 2005;14(2):114-119.
7. Gaasterland DE. Diode laser cyclophotocoagulation. *Glaucoma Today.* March 2009;7(2):35-37,41.
8. Tan AM, Chockalingam M, Aquino MC, et al. Micropulse transscleral diode laser cyclophotocoagulation in the treatment of refractory glaucoma. *Clin Exp Ophthalmol.* 2010;38:266-272.
9. Aptel F, Charrel T, Lafon C, et al. Miniaturized high-intensity focused ultrasound device in patients with glaucoma: a clinical pilot study. *Invest Ophthalmol Vis Sci.* 2011;52(12):8747-8753.
10. Aptel F, Denis P, Rouland J, et al. Ultrasonic circular cyclo coagulation in patients with primary open-angle glaucoma: preliminary results of a multicenter clinical trial. *Acta Ophthalmologica.* 2012;90:0. doi:10.1111/j.1755-3768.2012.F044.x.