

MicroPulse® Renews the Role of Laser Treatment in DME and Other Conditions



Charles Mayron, MD, FACS, is a vitreoretinal specialist with Capital Retina Associates in Latham, N.Y.

Even in today's anti-VEGF era when we can achieve previously unattainable outcomes for our patients, treating diabetic eye disease remains challenging. Anti-VEGF injections aren't effective in 100% of cases. Furthermore, when diabetic patients have multiple comorbidities, which is common, they're required to see several doctors, often leading to noncompliance with recommended follow-up schedules. As such, it's important to use all tools available to individualize treatment regimens and preserve vision.

While there has always been a place for traditional thermal laser treatment, its usefulness is restricted by its destructive nature and limited effectiveness. However, by incorporating MicroPulse Laser Therapy into my practice, I've been able to renew the role of laser. Using MicroPulse, I can deliver the efficacy of a laser option without damaging retinal tissue. Before I purchased a laser with MicroPulse capability, I was convinced by the science of the safety of subthresh-

old photostimulative treatments for macular applications.^{1,2} This is especially advantageous in diabetic macular edema (DME) cases involving the fovea, given the risk of injury to the fovea posed by traditional laser is not acceptable in the era of retinopharmacotherapy.

MicroPulse also is an effective and less invasive alternative to anti-VEGF treatment for non-center-involving DME and may be used for patients who want to avoid anti-VEGF agents. Whether I choose to use MicroPulse as first-line monotherapy or in addition to anti-VEGF, treatment usually depends on the extent of a patient's symptoms and central retinal thickness (CRT). I'm more likely to use anti-VEGF first and add MicroPulse later, if necessary, in patients with symptomatic visual acuity (VA) decline and/or CRT on OCT of 400 μ m or higher. An added benefit of using a combination of an anti-VEGF agent and MicroPulse for DME is the likelihood that fewer injections will be needed, which reduces treatment burden and costs. On the other hand, I'm inclined to start with MicroPulse alone in patients who have minimal foveal edema and mild symptoms.

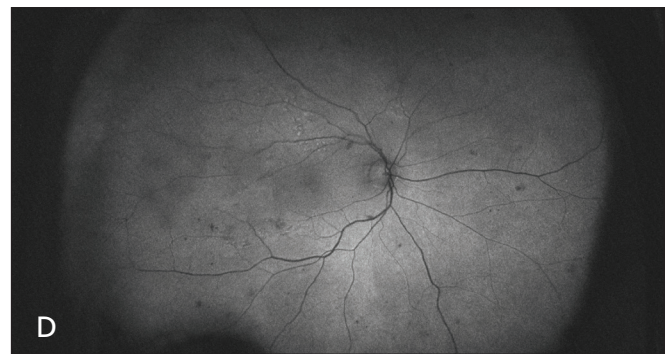
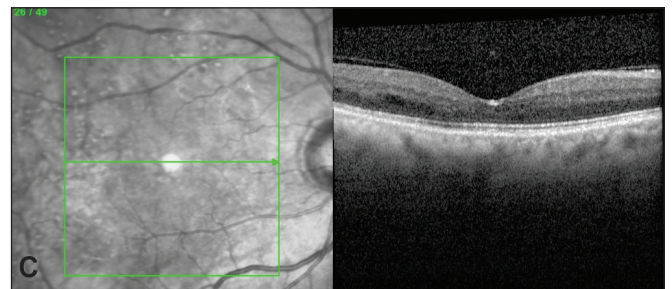
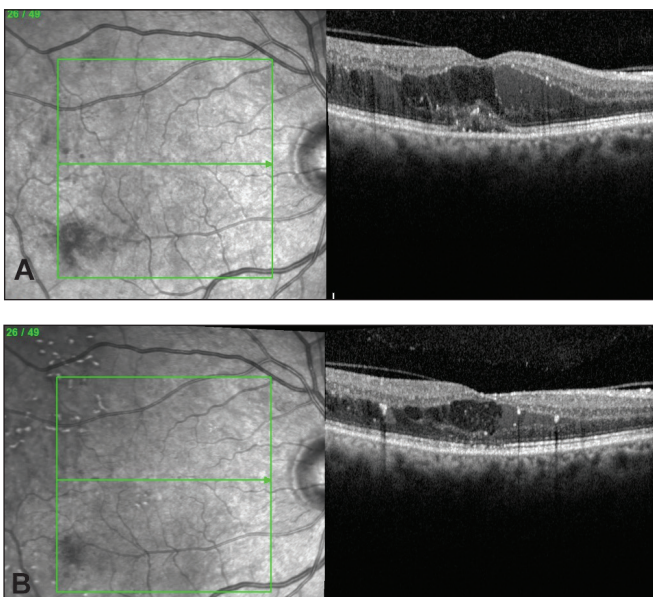


Figure 1. (A) Oct. 22, 2013 | pre-anti-VEGF, pre-MicroPulse | CRT 458 μ m | VA 20/40, (B) May 21, 2014 | post 3 anti-VEGF injections, pre-second MicroPulse | CRT 360 μ m | VA 20/30, (C) June 26, 2015 | 17 months post first MicroPulse, four months post fourth MicroPulse | CRT 206 μ m, no macular edema | VA 20/20-2, (D) no evidence of foveal MicroPulse treatment on fundus autofluorescence.

“An added benefit of using a combination of an anti-VEGF agent and MicroPulse for DME is the likelihood that fewer injections will be needed, which reduces treatment burden and costs.”

MICROPULSE TREATMENT IN CENTER-INVOLVING DME

This case involves a 77-year-old male who presented with DME on Oct. 22, 2013. His CRT was 458 μm and VA was 20/40 (Figure 1A). Starting that day, he received three monthly injections of ranibizumab (Lucentis, Genentech). When he returned on Jan. 29, 2014, a month after the third injection, he said his vision hadn’t improved at all. VA was 20/50. I recommended a MicroPulse treatment instead of a fourth Lucentis injection to help us reach the goal of a fluid-free retina, and the patient agreed (See Table 1). Two months after the first MicroPulse treatment, the patient reported his vision had improved. At the March 28, 2014 follow-up visit, CRT was 346 μm. By his visit on May 21, 2014, CRT had increased to 360 μm, yet VA improved to 20/30 (Figure 1B). He underwent a second MicroPulse treatment.

By the patient’s visit on Sept. 24, 2014, the MicroPulse treatments had produced a significant decrease in CRT, to 266 μm, but VA was less than ideal at 20/40

(pinhole to 20/25). Hoping to completely dry the retina and restore better vision, the patient received a third MicroPulse treatment. At the Dec. 24, 2014 follow-up appointment, we had reached our treatment goal. CRT was further improved to 211 μm, VA was 20/25, and macular edema was completely resolved. Given the recurring nature of the patient’s DME, we scheduled him for a Feb. 27, 2015 check up. At this time, the return of a low level of edema (218 μm) in the temporal area was detected. The patient consented to a fourth MicroPulse treatment. At his final visit on June 26, 2015, he was doing very well (Figure 1C): CRT was 206 μm, VA was 20/20 -2, and no macular edema was present. As I often do, I imaged the treated eye with fundus autofluorescence and wasn’t surprised that it showed no evidence of MicroPulse treatment in the fovea (Figure 1D).

KEY POINTS ABOUT MICROPULSE IN CLINICAL PRACTICE

I use MicroPulse to treat several retinal conditions in addition to DME, including central serous chorioretinopathy, macular edema secondary to vein occlusion, and select cases of AMD. I’ve gleaned several key points about how the treatment works. Three important ones, which this case nicely illustrates, are 1) it isn’t unusual for MicroPulse to take time to work, 2) it can be safely repeated, and 3) patients often report subjective improvement in their vision even in the absence of significant improvement in CRT. Also, the 5% duty cycle is crucial in enabling confluent, i.e., complete and thorough, yet safe treatment.³ Finally, the TxCell™ Scanning Laser Delivery System is indispensable for applying MicroPulse treatments accurately and efficiently. It’s also versatile. I use it with my IRIDEX IQ 577™ laser; not only for MicroPulse treatments, but also for traditional continuous-wave panretinal photocoagulation. ■

REFERENCES

1. Lavinsky D, Sramek C, Wang J, et al. Subvisible retinal laser therapy: titration algorithm and tissue response. *Retina*. 2014;34(1):87-97.
2. Luttrull JK, Sinclair SH. Safety of transfoveal subthreshold diode micropulse laser for fovea-involving diabetic macular edema in eyes with good visual acuity. *Retina*. 2014;34(10):2010-2020.
3. Vujosevic S, Martini F, Longhin E, et al. Subthreshold micropulse yellow laser versus sub-threshold micropulse infrared laser in center-involving diabetic macular edema: morphological and functional safety. *Retina*. 2015;35(8):1594-1603.

Table 1. TREATMENT PARAMETERS

IRIDEX IQ 577™ with TxCell-guided MicroPulse for DME

- Wavelength: 577 nm
- Spot size on slit lamp adapter: 100 μm
- Contact lens: QuadrAspheric (Volk)
- Power: 500 mW
- Exposure duration: 200 ms
- Duty cycle: 5%
- MicroPulse Delivery: 500 confluent spots in 7x7 TxCell grids applied to all edematous areas, including the fovea. The same parameters were used in all treatments except the fourth in which a lower power and fewer spots were used because the treatment area was smaller.



To learn more about MicroPulse, go to www.iredex.com/micropulse

Treatment techniques and opinions presented in this case report are those of the author. IRIDEX lasers are cleared for retinal photocoagulation of vascular and structural abnormalities of the retina and choroid; and iridotomy, iridectomy and trabeculoplasty in angle-closure glaucoma and open-angle glaucoma. IRIDEX assumes no responsibility for patient treatment and outcome. IRIDEX, IRIDEX logo, and MicroPulse are registered trademarks, and IQ 577 and TxCell are trademarks of IRIDEX Corporation.

IRIDEX | 1212 Terra Bella Avenue | Mountain View, CA 94043 | 800.388.4747 (U.S. inquiries) | info@iredex.com (U.S. & int'l inquiries) | www.iredex.com

© 2015 IRIDEX Corporation. All rights reserved. LT0631